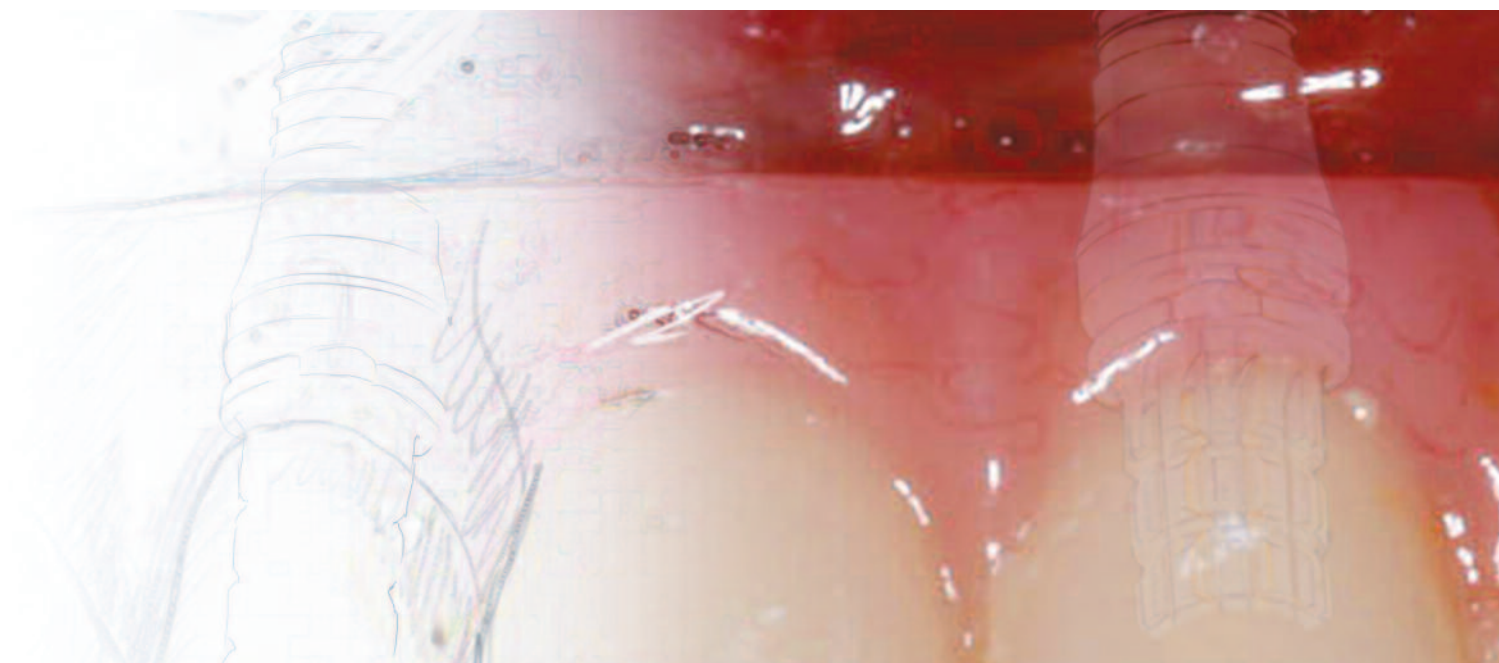

Inside this issue:

Treatment of maxillae: Clinical guidelines 7

Maxillary sinus surgery: Diagnostic imaging 18

The OSSEOTITE® 2 Certain® Implant 26

A staged approach to implant therapy 38

CT guided implant surgery 44

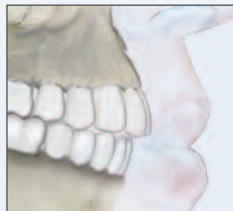Table of Contents



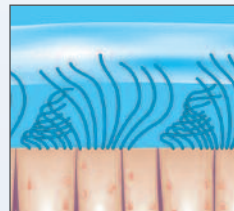
pg. 4
Editor Emeritus
Editorial
Richard J. Lazzara, DMD,
MScD



pg. 6
From the Editor
Patient-centered thinking
Anita H. Daniels, RDH



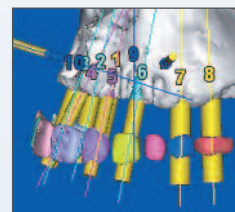
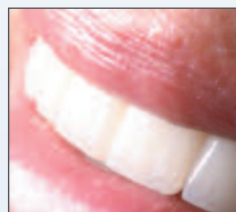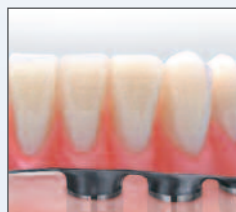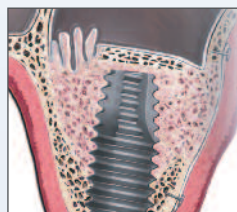pg. 7
Treatment of edentulous
and partially edentulous
maxillae: Clinical
guidelines
Joseph Carpentieri, DDS
Carl Drago, DDS, MS
USA



pg. 18
Maxillary sinus surgery:
Anatomy and advanced
diagnostic imaging
Tiziano Testori, MD, DDS
ITALY



pg. 26
The OSSEOTITE[®] 2
Certain[®] Implant: A one-
year interim report on a
prospective clinical and
radiographic study
Pär-Olov Östman, DDS, PhD
SWEDEN



pg. 35
 Editorial
 Can we successfully manage patients on bisphosphonate therapy?
 Robert E. Marx, DDS
 USA

pg. 36
 Literature Review
 The clinical and histologic efficacy of xenograft granules for maxillary sinus floor augmentation

pg. 37
 Literature Review
 Volumetric determination of the amount of misfit in CAD/CAM and cast implant frameworks: A multicenter laboratory study

pg. 38
 A staged approach to implant therapy for a patient transitioning from partial removable prostheses to fixed implant-supported restorations
 Robert G. Ritter, DMD
 Karina Leal, DMD
 USA

pg. 44
 Treatment of atrophic maxillae with computed tomography guided implant surgery
 Robert A. del Castillo, DMD
 Thomas Peterson, CDT, MDT
 USA



EDITORIAL TEAM

Editor Emeritus

Richard J. Lazzara, DMD, MScD[†]

Editor

Anita Daniels

Clinical Editors

Harold S. Baumgarten, DMD[†]

Carl J. Drago, DDS, MS[†]

John A. Lupovici, DDS[†]

Alan M. Meltzer, DMD, MScD[†]

Pär-Olov Östman, DDS, PhD[†]

George F. Priest, DMD[†]

Research Editor

J.E. Davies, BDS, PhD, DSc[†]

Medical Illustration

Robin deSomer Pierce, BSMI

Graphic Design

Nate Fanberg

Web Design

Tim Doherty

Web Support

Rob Barrett

Justin Hair

The Journal of Implant and Reconstructive Dentistry (JIRD) is published by BIOMET 3i LLC, 4555 Riverside Drive, Palm Beach Gardens, Florida, USA 33410. Telephone: 561.776.6700. Certain, Encode, EP, GingiHue, Gold-Tite, JIRD, Journal of Implant and Reconstructive Dentistry, Navigator, OsseoGuard, OSSEOTITE, PreFormance, and QuickBridge are registered trademarks and BellaTek, IIRD, and NanoTite are trademarks of BIOMET 3i LLC. BIOMET is a registered trademark and BIOMET 3i and design are trademarks of BIOMET, Inc. Endobon is a registered trademark of BIOMET Deutschland GmbH. incise is a trademark of Renishaw, Plc. Actonel is a registered trademark of Warner Chilcott Company, LLC. BONIVA is a trademark of Roche Therapeutics Inc. Fosamax is a registered trademark of Merck & Co., Inc. 3M, ESPE, Imprint, and Penta are trademarks of 3M ESPE. PATTERN RESIN is a trademark of GC America. Temrex is a registered trademark of Temrex Corporation. ©2011 BIOMET 3i LLC. All rights reserved.

Opinions expressed in the articles and communications in both print and on the JIRD website are those of the authors and not necessarily those of the Editor(s) or Publisher. The Editor(s) and Publisher disclaim any responsibility or liability for such material. The clinical techniques presented in JIRD are representative of the individual clinician's experience in clinical practice and may not be indicative of other clinical cases or outcomes due to varying patient subsets and clinical scenarios. Reading an article in JIRD does not necessarily qualify you to integrate new techniques or procedures into your practice. JIRD expects its readers to exercise judgment regarding their expertise and, when necessary, recommends further education prior to the implementation of any new procedure.

[†]The contributing clinicians have financial relationships with BIOMET 3i LLC resulting from speaking engagements, consulting engagements, and other retained services.

EDITORIAL ADVISORY BOARD

Crawford Bain, DDS (SCOTLAND)

Carlo Bianchessi, MD, DDS (ITALY)

Michael Block, DMD[†] (USA)

José Luís Calvo-Guirado, DDS, PhD, MS (SPAIN)

Joseph R. Carpentieri, DDS[†] (USA)

Stephen J. Chu, DMD, MSD, CDT[†] (USA)

Roberto Cocchetto, MD, DDS[†] (ITALY)

Mithridade Davarpanah, MD[†] (FRANCE)

Robert A. del Castillo, DMD[†] (USA)

Robert W. Emery, DDS (USA)

Israel M. Finger, BDS, MS, M. Ed, DDS[†] (USA)

Ronnie J. Goené, DDS[†] (NETHERLANDS)

Ueli Grunder, DMD[†] (SWITZERLAND)

Robert L. Holt, DMD, PhD (USA)

Markus Hürzeler, DMD, PhD[†] (GERMANY)

Juan Carlos Ibañez, DDS (ARGENTINA)

Curtis E. Jansen, DDS[†] (USA)

Gregory J. Keiser, DMD (USA)

Perry R. Klokkevold, DDS, MS (USA)

Robert M. London, DDS[†] (USA)

Robert Marx, DDS (USA)

Ziv Mazor, DMD (ISRAEL)

Richard A. McCall, DDS MS (USA)

Konrad Meyenberg, DDS[†] (SWITZERLAND)

Craig M. Misch, DDS, MDS (USA)

Gary A. Morris, DDS[†] (USA)

Rich Napolitano, CDT[†] (USA)

Keith Progebin, DDS[†] (USA)

Christopher Ramsey, DMD[†] (USA)

Robert G. Ritter, DMD[†] (USA)

Alan L. Rosenfeld, DDS, FACD[†] (USA)

Bruce E. Rotter, DMD (USA)

Anthony G. Sclar, DMD (USA)

Michael K. Sonick, DMD[†] (USA)

Tiziano Testori, MD, DDS, FICD[†] (ITALY)

Xavier Vela-Nebot, MD, DDS (SPAIN)

Lee R. Walker, MD, DDS[†] (USA)

Stephen S. Wallace, DDS[†] (USA)

Stephen L. Wheeler, DDS (USA)

editorial

Editor Emeritus



Treating the edentulous maxilla presents many more challenges than treating the edentulous mandible. This is true for patients who are already edentulous and those who will become edentulous prior to having implants placed. The challenges include aesthetic, phonetic, and implant-placement challenges, as well as prosthetic and loading issues.

Various techniques can be used to manage restorations placed in the edentulous maxilla. Considerations vary from the number of implants required to the types of prosthetic components used in both the transitional and definitive prostheses. Developing a transitional prosthesis for the patient immediately upon implant placement has numerous advantages. Psychological advantages for edentulous patients include elimination of their maxillary dentures. For partially edentulous patients who will be edentulated during the implant-placement process, psychological advantages include avoidance of ever having a complete denture. Patients have immediate gratification or an immediate result from the surgical procedure relative to their prosthetic stability and function, as well as their appearance.

Additionally, prosthetic advantages include early evaluation of the adequacy of lip support, phonetics, and function prior to arriving at the definitive restoration stage. Soft-tissue enhancements or guidance of soft-tissue contours is also often a benefit of having a fixed transitional appliance. The patient who previously wore a removable denture for many years can begin a new daily self-care regime and develop the dexterity necessary for optimal oral hygiene.

In the edentulous maxilla, bone dimensions are often inadequate, and vertical and/or horizontal augmentation may be required to enable positioning of implants of adequate length or placing them in the correct position for prosthetic support. Because of the resorptive nature of maxillae, the occlusal relationship and lip-support requirements of the maxillary prosthesis are much different from those of the mandibular prosthesis. Therefore, treatment of edentulous maxillae requires alterations in implant position and more grafting than similar situations in the mandible. Additionally, research shows that immediate loading of implants results in more initial bone-to-implant contact. Aesthetic demands are considerably greater. Soft-tissue and hard-tissue augmentation procedures are generally associated with management of the complete restoration of the maxillary arch.

While challenges are multiple, benefits are significant for both the clinician and the patient. Immediate restoration of the maxillary arch is a rewarding service for clinicians to provide to patients. It also helps in developing patients as a good referral source.

Sincerely,

A handwritten signature in black ink, appearing to read 'Richard J. Lazzara'.

Richard J. Lazzara, DMD, MScD[†]
Editor Emeritus

[†]The contributing clinician has a financial relationship with BIOMET 3i LLC resulting from speaking engagements, consulting engagements, and other retained services.

TAKE A FRONT ROW SEAT
TO TOMORROW'S TECHNIQUES.



 The **INSTITUTE**
for
Implant & Reconstructive Dentistry
Education Through Innovation.

From the Editor

editorial

Patient-centered thinking



This issue of JIRD is focused on rehabilitation of the maxilla and begins with treatment guidelines formulated by Drs. Joseph Carpentieri and Carl Drago. A core concept underlying these guidelines is the need to first understand patients' chief complaints or concerns about their existing clinical situation, along with their treatment goals. Oftentimes, patients simply desire more retention for their removable prostheses. Alternatively, they may want to eliminate the removable aspect, instead obtaining a fixed solution for replacing their missing teeth.

Understanding the patient's preferences, finances, and clinical factors are all crucial to formulating a successful treatment plan. Clinical studies indicate that not only technical aspects determine patient satisfaction with given treatments; patient-related treatment outcomes may also be important determinants for success. These include perceptions of general comfort, aesthetics, masticatory function, and speech. Since the patient's assessment of a successful outcome may be the determining factor of overall success, treatment based on patient-centered thinking is the most likely to be judged successful.

Edentulism imposes functional and aesthetic burdens on individuals and worsens quality of life. Tooth loss also can compromise the psychosocial well-being of even patients who seem to adjust reasonably well to a conventional denture. Dierens et al¹ found that more than 90% of their study patients preferred a single-stage surgical approach to the classical protocol.

The clinical case presentations included in this issue demonstrate approaches to treatment of the maxillary arch following the Carpentieri/Drago guidelines. Clinicians contributing to this issue are from around the globe and share their experiences of using different treatment approaches and techniques to provide their patients with optimal outcomes. A variety of protocols and new technological advances are demonstrated, including guided surgery, fabrication of provisional prostheses placed in immediate loading protocols, and serial or staged approaches to treatment.

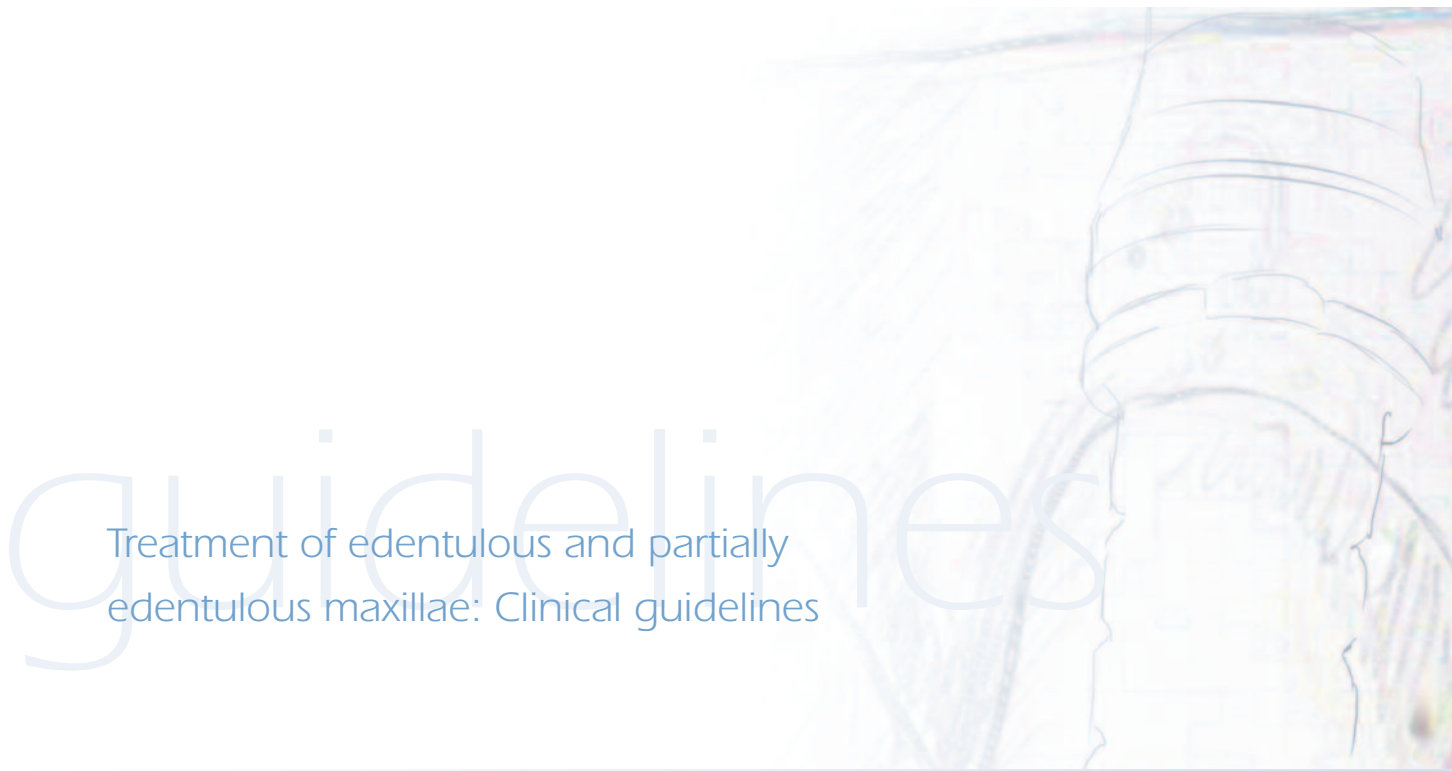In our youth-centric society, the psychological advantages for patients who are treated with immediate or transitional protocols are numerous. As dental professionals, we should start by listening to our patients' concerns and educating them as to the possible options for treatment to address those concerns. From that point, an optimal treatment plan can be created. A patient's aspirations should be well understood and the treatment plan developed accordingly.

Sincerely,

Anita H. Daniels, RDH†
Editor

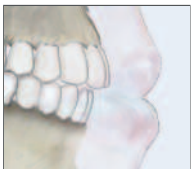1. Dierens M, Collaert B, Deschepper E, et al. Patient-centered outcome of immediately loaded implants in the rehabilitation of fully edentulous jaws. *Clin Oral Implants Res.* 2009;20(10):1070-1077.

†Global Director of Professional Communications, BIOMET 3i.



Treatment of edentulous and partially edentulous maxillae: Clinical guidelines

Joseph Carpentieri, DDS[†] & Carl Drago, DDS, MS[†]



Edentulous maxillae differ from edentulous mandibles in their resorptive and loading patterns, as well as in the bone quality and quantity typically associated with both. Consequently, clinical guidelines for treating each arch must differ. This article presents a literature-based, systematic approach aimed at helping clinicians with treatment planning and the decision-making process for maxillary treatment. The process requires balancing patient preferences and finances with a number of clinical factors. Because the choice of fixed versus removable options for both provisional and definitive prostheses is often the most difficult step in treatment planning, special attention is given to considerations regarding both.

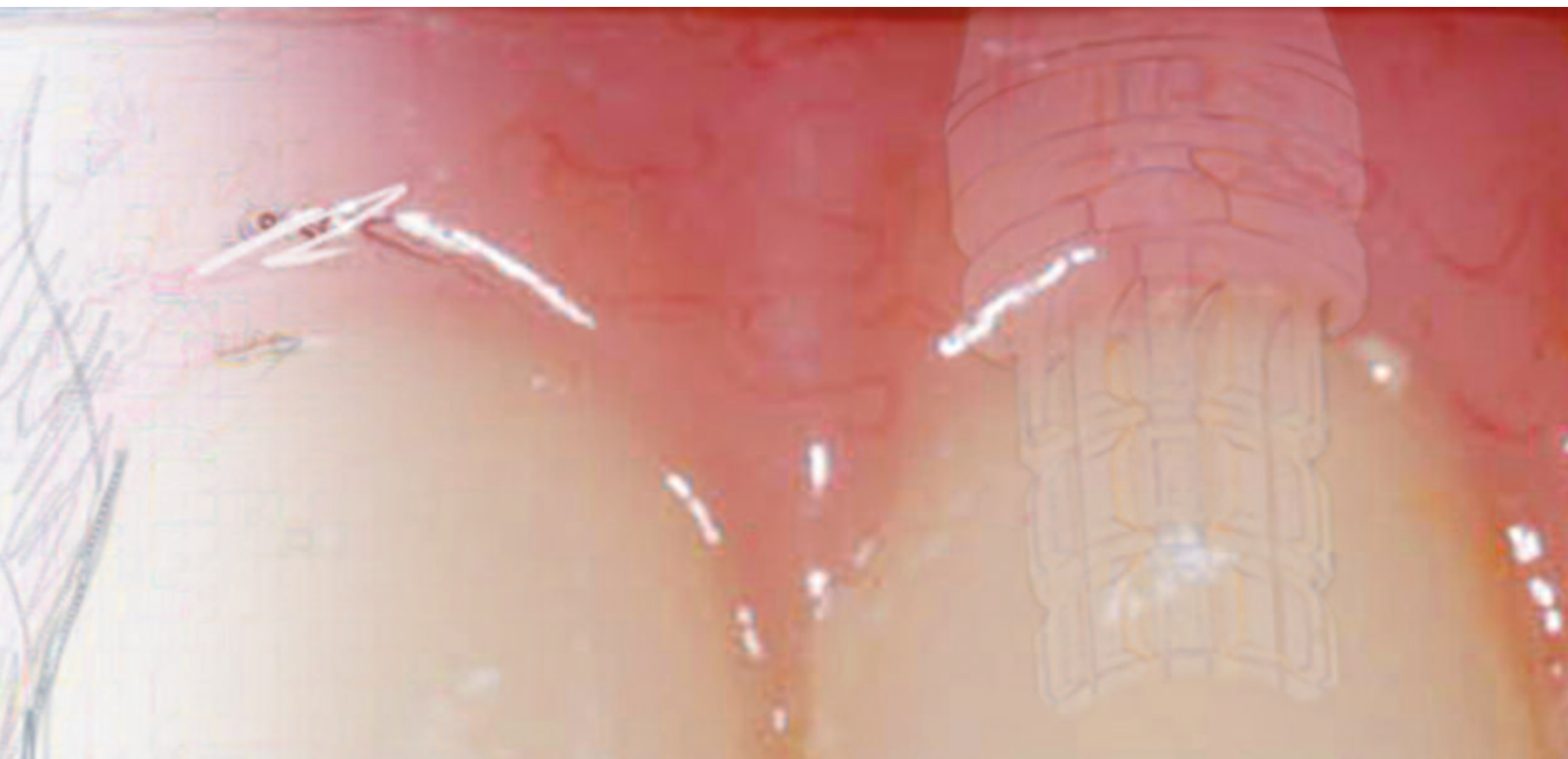Key Words: maxillae, clinical guidelines, treatment planning, implants

Introduction

Despite advances in modern dentistry, age-specific rates of edentulism are expected to increase over the next several decades in most industrialized countries throughout the world.^{1,2} It is important to note that these studies do not take into account partially edentulous patients with severely compromised teeth; this segment of the population represents a large and important group of patients who will also be seeking care.

The goal of early implant researchers was to eliminate mandibular complete dentures and treat patients with edentulous mandibles with fixed-implant prostheses.³

Over the past two decades, numerous worldwide studies have demonstrated that the mandibular two-implant overdenture is a simple and effective option.^{4,5} This has led to a shift in therapeutic philosophy and eventually to the development of the McGill Consensus Statement on Overdentures.⁶ The consensus suggested “the mandibular two-implant overdenture was the first-choice minimal-treatment objective for edentulous patients.” Current concepts for edentulous mandibles include both fixed and various removable options that often lead to high levels of implant success, prosthesis survival, and a consistently high level of patient satisfaction.⁷



Maxillary treatment presents different challenges. Based on a careful review of the literature,⁸ the present authors would like to suggest that the most appropriate starting point among a hierarchy of acceptable treatment options is a thorough examination and diagnosis of the edentulous (or partially edentulous) condition prior to treatment planning. However, decision-making may still be confusing for a significant number of clinicians. How does one choose among various fixed and removable designs? What is the correct/optimal number and position for implants? Does splinting implants improve implant survival? How are mandibular guidelines applied to the maxilla?

Treatment of edentulous maxillae should be considered different from that of edentulous mandibles for the following reasons:

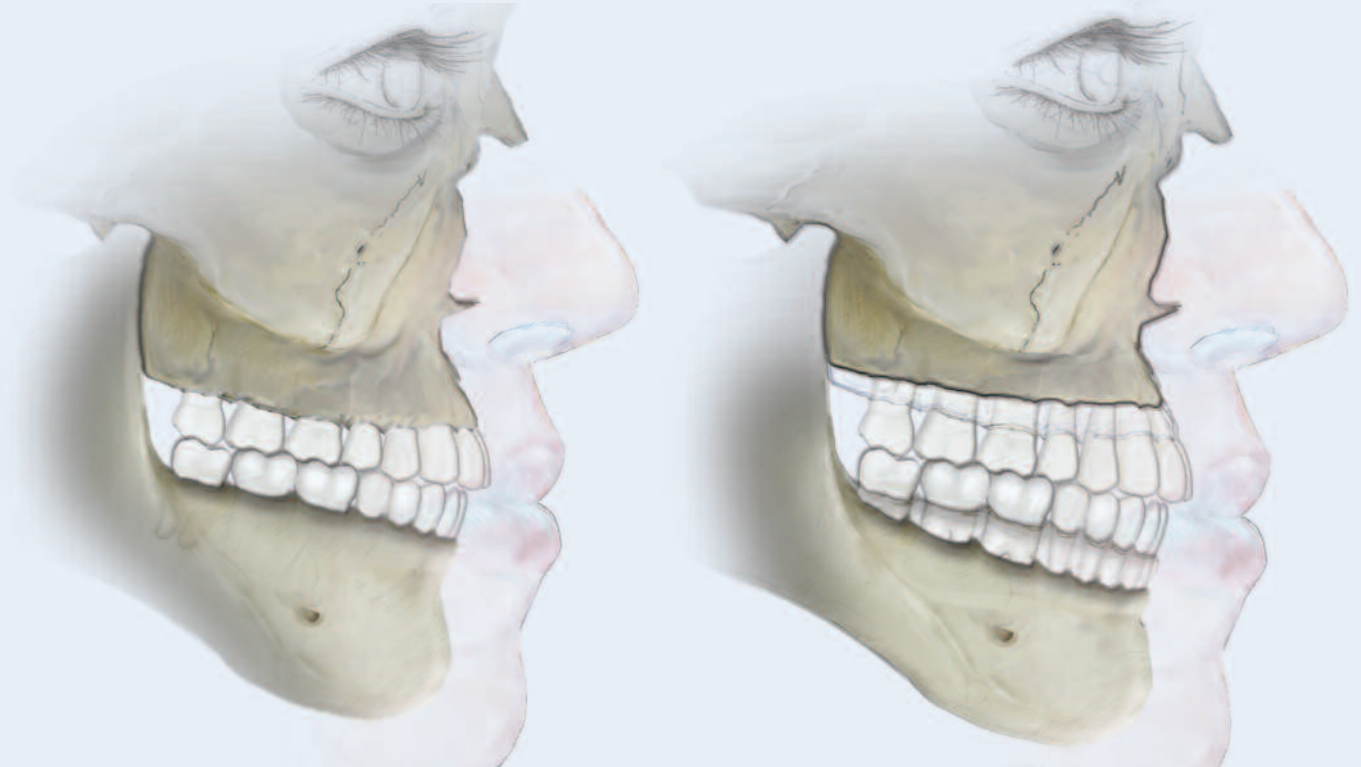1. **Different Resorptive Patterns:** Maxillae resorb superiorly, posteriorly, and medially, while mandibles resorb inferiorly, anteriorly, and laterally (Fig. 1).^{9,10} These differences often lead to unfavorable implant relationships between the opposing jaws.
2. **Anatomic Factors:** Multiple studies indicate that bone density is one of the most important factors for implant success.^{11,12}

Maxillae generally present with less bone quality (density) as compared to mandibles. The maxillary and nasal sinuses also are associated with diminished quantities of bone.¹³

3. **Loading Patterns:** Because maxillae are stationary, with loss of teeth and proprioceptive mechanisms, they are ill-equipped to respond to large occlusal forces.¹⁴⁻¹⁶

To compensate for these factors, surgical treatment plans can be developed that include such strategies as optimally positioning an adequate number of implants, undersizing the osteotomies, and using tapered implant designs. In the prosthetic phase of treatment, three factors are mostly affected by maxillary determinants.¹⁷

1. **Aesthetics:** Oral/facial symmetries and lip contours are significantly influenced by maxillary tooth positions, vertical dimensions, and/or the need for flanges of varying thicknesses for lip support.^{18,19}
2. **Phonetics:** It is important to understand that maxillary prostheses affect speech more than mandibular prostheses. Patients have identified speech quality as a major factor in perceived satisfaction with their prostheses.²⁰⁻²³



3. Prosthesis Design and Fabrication: Clinicians must understand technical difficulties, fabrication options, material choices for replacing large volumes of missing tissues, and precision fit issues prior to developing maxillary treatment plans.^{24,25}

Clinical guidelines established for treating edentulous mandibles should not be directly extrapolated to treatment of edentulous maxillae. Rehabilitation of edentulous maxillae is significantly more complex.

The purpose of this article is to present a literature-based, systematic approach that will aid clinicians in the decision-making process specifically related to the maxilla, including:

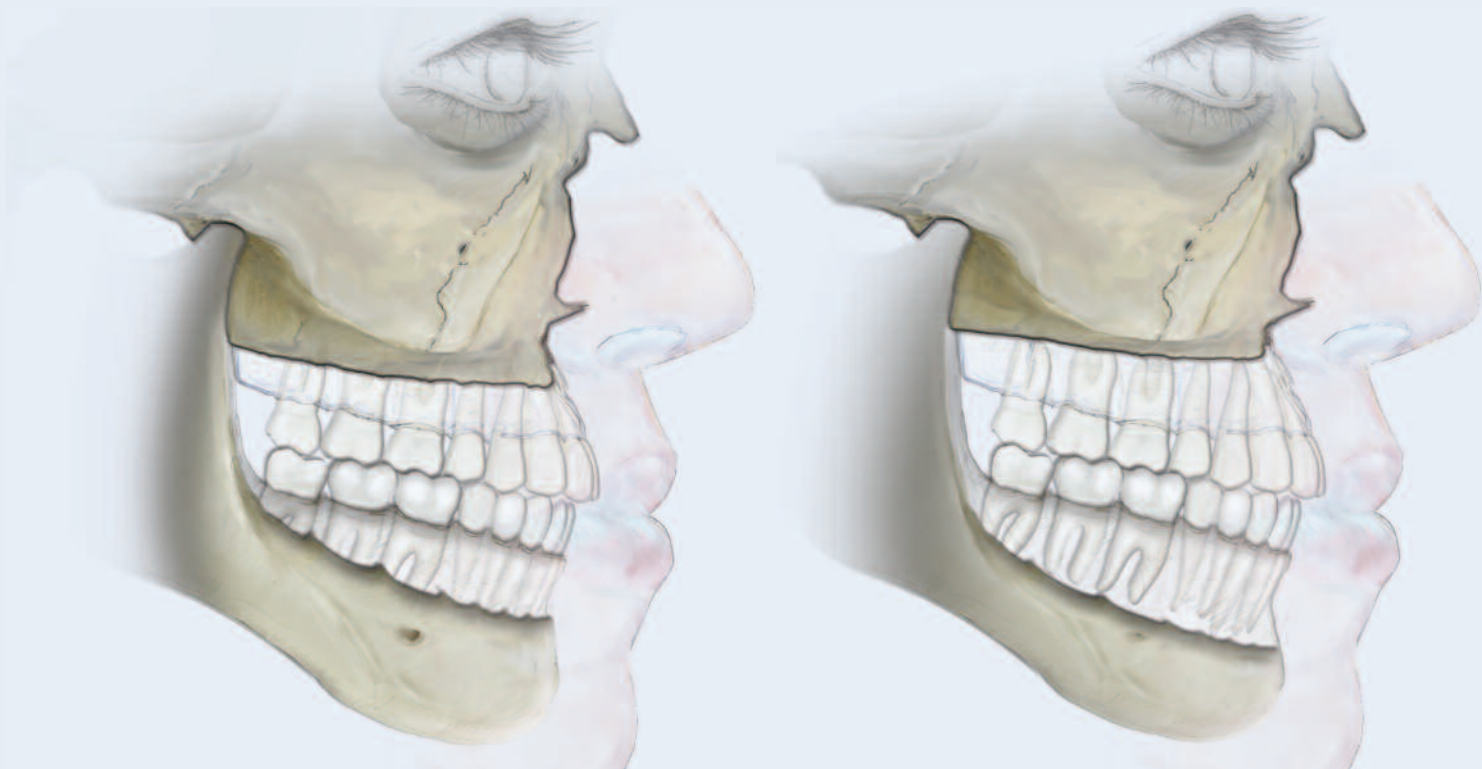
- The patient interview
- Collection of basic diagnostic data
- Discussion of provisional restorative options
- The decision-making process
- The confirmation letter

I. Patient Interview

Without question, the patient interview is the first and most important step in this process.²⁶ History-taking is both an art and a science. What is said in response to questions is as important as the way it is said; what is omitted is also important. A thorough dental and medical history should be part of the patient interview.

It is important to understand that edentulism and partial edentulism affect patients on personal and emotional levels. When replacing lost teeth, clinicians need to consider patients' specific needs, psychological considerations, and personal objectives and preferences.²⁷ Sufficient time should be devoted to asking patients about their expectations, rather than telling them what they need. Table I suggests some questions for inclusion in the patient interview.

It is important for patients to understand that there are numerous options available to meet their specific needs, and that the benefits, limitations, and financial commitments required for each option vary. To most efficiently direct the decision-making process, basic financial considerations should be reviewed at this initial interview appointment.



II. Collection of Basic Diagnostic Data

A thorough clinical examination, diagnostic casts, diagnostic wax patterns, radiographs, and an evaluation of intra- and extra-oral factors are all necessary early in the treatment process.

On the most basic level, patients will be differentiated as dentate, partially edentulous, or edentulous. For edentulous patients, the first step in prosthetically driven treatment planning is to determine ideal tooth positions. Patients who present with existing dentures should be evaluated with and without the dentures in place. Such evaluation can yield significant information about the ideal tooth positions, vertical dimension of occlusion, vertical dimension at rest, and whether or not a flange is needed for facial and lip support. If the patient's existing denture is unsatisfactory, a wax denture should be fabricated to enable agreement between the patient and clinician about tooth position and facial/lip support. Additionally, this wax denture should be evaluated with both a full and partial (cut back) flange.

Clinicians need to assess the general ridge anatomy, inter-arch distance, and inter-arch relationships. Articulated casts usually

provide significant data in this regard. Clinicians also need to consider what structures are missing and what replacement materials may be used in the rehabilitation.²⁸ Once the aesthetic outcome has been agreed upon, the wax denture prosthesis should be duplicated for use as a conventional surgical guide with three-dimensional analysis (cone-beam computerized tomography (CBCT)) or for CT guided surgery.

According to the American Academy of Oral and Maxillofacial Radiology, "a single panoramic image is not sufficient for pre-surgical dental implant-site assessment."²⁹ An accurate diagnosis and subsequent treatment plan may only be determined in conjunction with three-dimensional analysis; this should be considered basic diagnostic information.

After the diagnostic data have been collected, the factors summarized in Table 2 will favor either a fixed or removable treatment option.

However, the definitive choice between fixed or removable treatment options cannot be solely based on the factors presented in Table 2. Deciding between those options is often the most difficult step in the treatment-planning process.

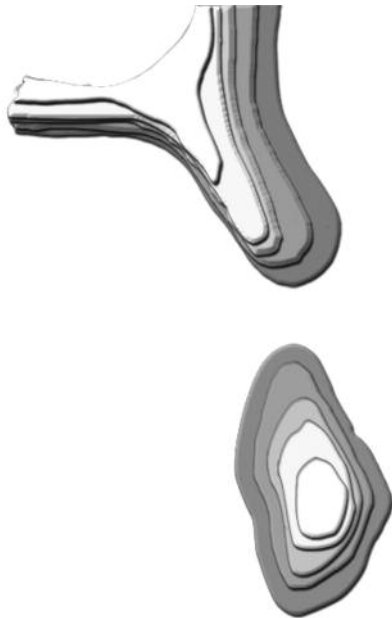


Fig. 1. Schematic drawing showing that maxillae resorb superiorly, posteriorly, and medially. In contrast, mandibles resorb inferiorly, anteriorly, and laterally.

III. Discussion of Provisional Restorative Options

After interviewing the patient and evaluating the diagnostic data, clinicians need to review with patients the provisional restorative options that are available to them. Discussion of these options early in the process has an enormous impact on case acceptance. Once the type of provisional prosthesis has been chosen, this choice will assist clinicians in designing the definitive prosthesis (fixed/removable). Moreover the treatment sequence will influence the choice of how many implants must be placed and where they will be positioned.

Each provisional prosthetic option has benefits and limitations. Treatment options for fixed prostheses include the following:

1. Serial Extraction Protocol: For partially edentulous patients with periodontally compromised teeth, clinicians may consider a serial extraction protocol. This protocol involves the selective extraction of teeth, with or without immediate implant placement. If implants are not placed immediately, the extraction sites should be grafted to maintain the volume of the alveolar ridge.³⁰ Full-crown preparations of the remaining teeth and conventional tooth-supported provisional prostheses are also typically required. This option is often the treatment of choice.³¹

For Patients:

- How can I help you?
- What are the treatment goals that you would like to achieve?
- Are you satisfied with your appearance?
- For patients wearing removable prostheses:
 - Do you need improved retention?
 - Would you like to be able to feel the roof of your mouth and cut out the palatal aspect of the denture?
 - Would you like to eliminate the removable prosthesis altogether and replace it with a prosthesis that does not come in and out?

For Clinicians:

- What type of provisional prosthesis is appropriate?
- Will the patient tolerate a removable provisional prosthesis at any time or does the patient want/have to be maintained with a fixed provisional prosthesis?

Table 1. Patient interview questions.

2. Extractions and Immediate Implant Placement with or without Immediate Provisionalization:

Immediately after tooth extraction, implants may be placed and restored with provisional prostheses.^{32,33} Clinicians should proceed with great caution if this protocol is selected, as compromised tooth positions may lead to aesthetic, phonetic, and other difficulties with the definitive prostheses.

3. Immediate Provisional Restorations:

Implants may be placed in healed sites and restored with immediate provisional prostheses. Immediate loading of a maxillary fixed implant prosthesis requires careful case selection but is considered scientifically and clinically valid. One- to three-year implant-survival rates range from 95.4-100%, and prosthesis-survival rates range from 87.5-100%.³⁴⁻³⁹ In these studies, prostheses generally were full-arch, one-piece, cross-arch-stabilized designs supported by four to eight implants placed with adequate initial insertion torque.

4. Interim Removable Prostheses:

For patients with removable provisional prostheses who will be receiving fixed definitive prostheses, it is essential eventually to fabricate fixed provisional prostheses. This is necessary to determine aesthetic final tooth positions and

Intraoral Factors	Fixed Prosthesis	Removable Prosthesis
General ridge anatomy	Adequate B/L width	Inadequate width, buccal concavity
Interarch clearance	10mm or less	Greater than 15mm
Skeletal jaw relationship	Class I or moderate Class II	Class III
Facial/lip support	Not needed	Required

Table 2. Evaluation and summary of intraoral and extraoral factors.

emergence profiles of the abutments and definitive prostheses, as well as to establish the palatal contours of the prostheses for optimal phonetics. These provisional prostheses will be used as a prototype for the definitive prostheses. It is difficult and unpredictable for both patients and clinicians to transition from removable provisional prostheses to definitive fixed prostheses without some interim use of fixed provisional prostheses.

If the treatment plan includes a removable definitive prosthesis that will change the patient's lip support and overall aesthetic appearance, new interim dentures should be fabricated. If the existing prostheses are satisfactory, clinicians may choose to have patients continue to wear those prostheses. Diagnostic wax patterns for surgical guides are mandatory unless tooth positions will not be altered. For definitive removable prostheses, fixed provisional prostheses need not be discussed as a treatment option.

The importance of provisional prostheses cannot be overemphasized.

IV. The Decision-Making Process

The decision-making process must balance three key factors.

Patient Preferences: It is important to understand the difference between wants and preferences. "Wants" may or may not be related to treatment realities; "preferences" means that patients have clear understandings of the advantages and disadvantages of a given type of prosthesis. Clinicians should use the interview process, along with an understanding of the diagnostic factors, to turn the "wants" into "preferences." The benefits and limitations of each design, including maintenance (aftercare) considerations

and costs, must be explained. All full-arch implant prostheses require some degree of prosthetic maintenance. An understanding of these requirements and costs, as well as the limitations inherent in removable prostheses (movement, palatal coverage, unnatural feeling), will significantly assist patients in arriving at an optimal treatment choice.

Studies clearly indicate that with patient-centered care, when patient preferences are taken into consideration in the decision-making process, patients tend to do better with the treatment.⁴⁰

Finances: Cost is often the most significant factor for patients deciding among treatment options. It is therefore critical to present patients with realistic options. If a fixed definitive prosthesis is simply unaffordable, clinicians should recognize this and offer a removable prosthetic option (or options).

Clinical Factors: These include the bone quality and quantity. In addition, clinicians need to consider the form of the ridge (V-shaped versus U-shaped) relative to the anterior/posterior (A-P) spread (or other biomechanical factors), as well as the skeletal jaw relationships.

Other Fixed Versus Removable Considerations

Number of Implants

There is no consensus on the ideal number of implants needed to support either fixed or removable restorations, and the number of implants being placed should not be the determining factor in choosing a fixed versus removable option. The literature does indicate that four to six implants are sufficient to support both fixed and removable prostheses.^{35,36,38,41} It is important to relate the number of implants to the number of planned prosthetic teeth. Fewer implants are required for shortened arch treatment (premolar occlusion). The final decision about the number of

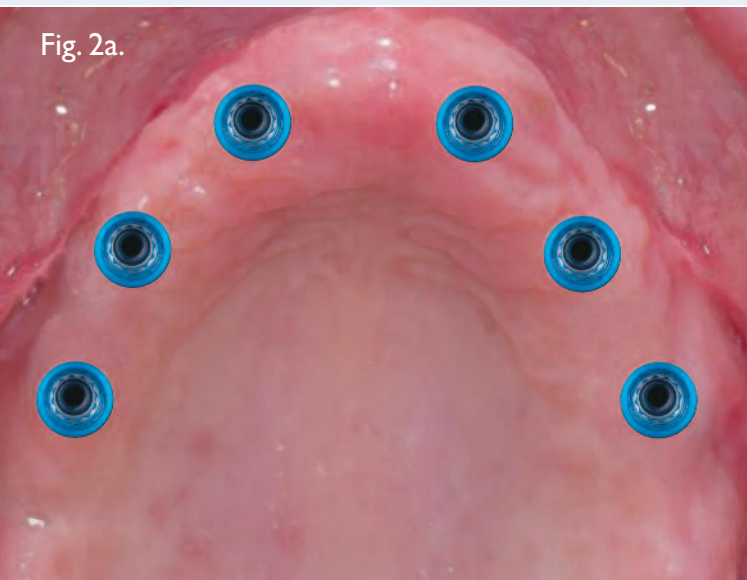


Fig. 2a.

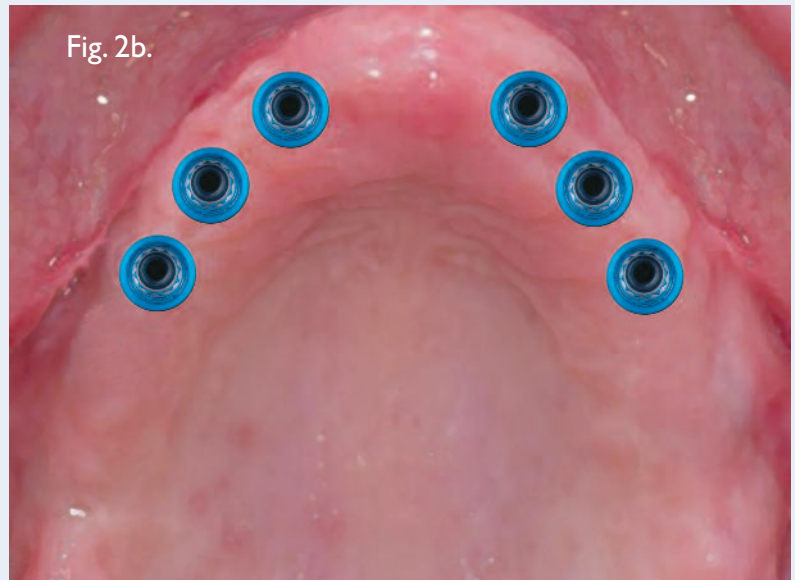


Fig. 2b.

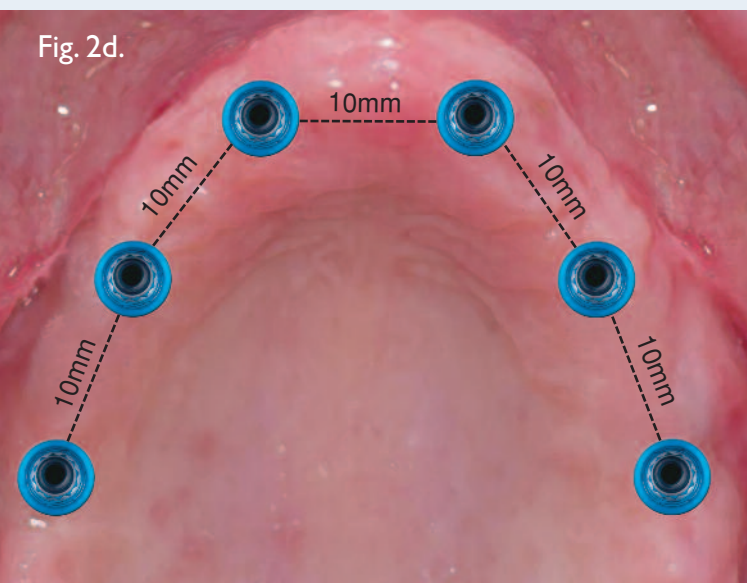


Fig. 2d.

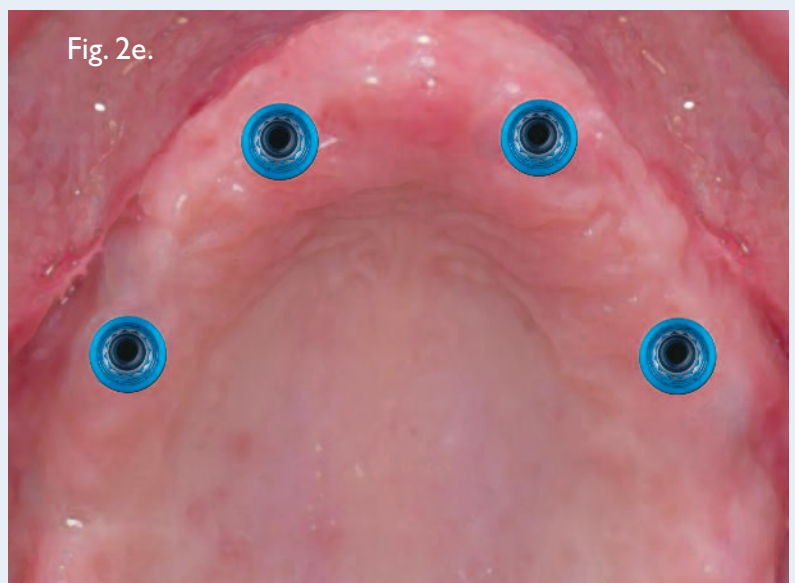


Fig. 2e.

implants is often based on aesthetic parameters (design of the prosthesis, need for a flange) and other patient-specific factors (e.g. bone-grafted sites, parafunction) and psychological factors.

Location of Implants

It is critical to understand that implant-placement locations influence the choice of fixed versus removable prostheses. Whereas either an anterior concentration or a wide distribution of implants is acceptable for maxillary fixed prostheses, only a wide distribution is recommended for removable prostheses. Furthermore, whereas either rigid

or non-rigid (resilient or rotational) removable prostheses are acceptable in the mandible, maxillary removable prostheses must have multiple retentive elements and no rotation, in addition to being supported by widely distributed implants.

Figures 2a-f demonstrate clinical examples of multiple numbers and varying locations of implants for maxillary treatment. Without further diagnostics (e.g. articulator mounting), it is impossible to make a decision relative to fixed versus removable treatment options.

Fig. 2c.

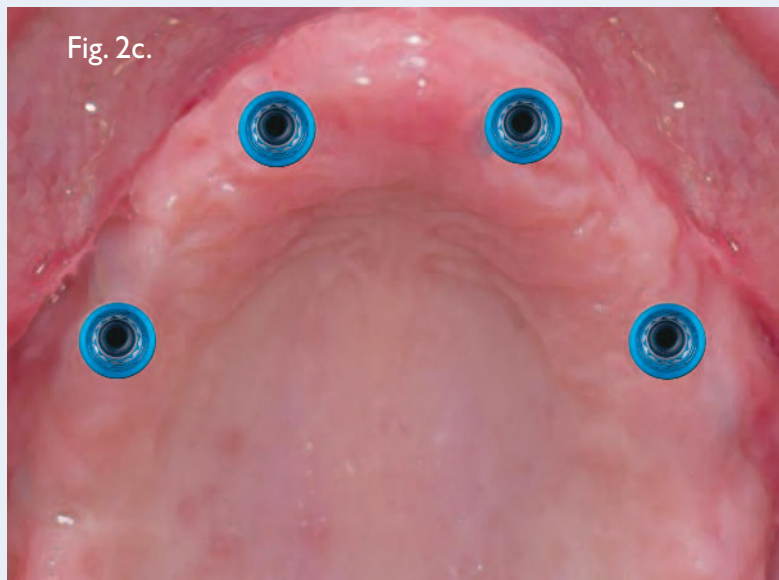


Fig. 2a. Fixed Prosthesis: It is ideal to place six implants, with fewer implants positioned anteriorly (where aesthetics are enhanced by avoiding implants next to each other). In this situation, more implants may be positioned posteriorly (for first molar occlusion). This arrangement applies to large or small, V- or U-shaped arches.

Fig. 2b. Fixed Prosthesis: An alternative treatment plan when six implants are placed is to concentrate the implants in the anterior segment, with exact positioning dependent on the tooth size, position, and quantity/quality of bone. Cantilevered pontics may be provided distal to the second premolar or first molar to avoid sinus grafting. This arrangement may be most ideal for V-shaped arches where the A-P spread is optimal.

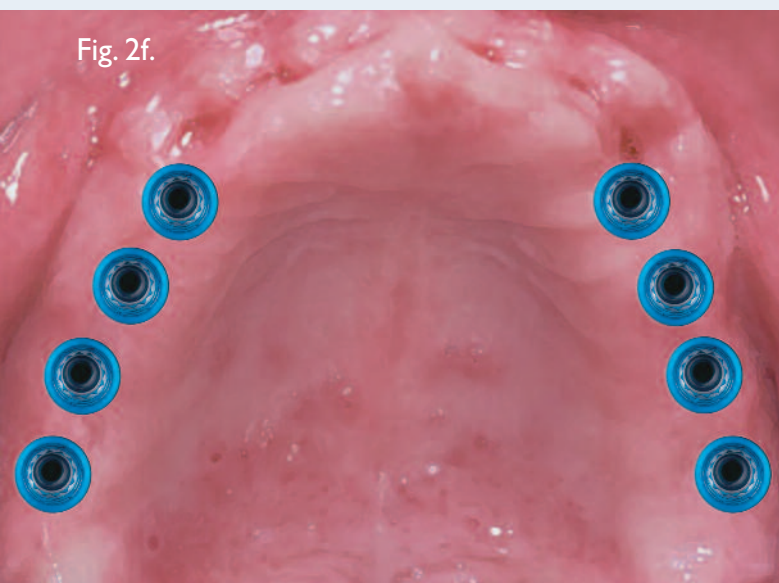
Fig. 2c. Fixed Prosthesis: Depending on the quality and quantity of bone, four implants may be placed but should be positioned to optimize the A-P spread. The posterior implants may be tilted to follow the anterior walls of the maxillary sinus. Angled abutments would be required to correct the non-vertical implant angulations. This implant arrangement may result in shorter prostheses (second bicuspid occlusion). Placing fewer implants requires careful case selection and is most ideal for V-shaped arches. The amount or lack of tooth display during speaking and smiling is critical.

Fig. 2d. Removable Prosthesis (splinted or unsplinted): The placement of six implants continues to be ideal, but the implants must be distributed widely with the center of each implant placed at least 10mm from the center of the adjoining implants. There needs to be adequate space for placement of the denture teeth, base, and attachments facial to the framework. Implant positioning is similar to that for fixed prostheses, but generally the mesial-distal positioning is less critical, since embrasure spacing and aesthetics are not critical. This implant arrangement can provide second molar occlusion and can be used for either large or small, V- or U-shaped arches.

Fig. 2e. Removable Prosthesis: Depending on the quality and quantity of bone, four implants may be placed, but it is essential to achieve a wide distribution (similar to implant positioning for fixed prostheses). Implants should be placed more palatally. The posterior implants may be tilted to follow the anterior walls of the maxillary sinus. Angled abutments would be required to correct the non-vertical implant angulations. For maxillary removable prostheses, anterior concentrations of implants should be avoided. This implant arrangement is ideal for smaller V-shaped arches.

Fig. 2f. Removable or Fixed Prosthesis: If sinus grafting has been accomplished but it is not possible to predictably augment anterior bone, as many as eight implants may be placed in more posterior positions. This arrangement can be applied to either large or small, V- or U-shaped arches.

Fig. 2f.



Space Considerations

Although overdentures are recommended for severely atrophic arches, this option paradoxically requires the most restorative space. Careful pre-operative planning is essential.⁷ In the vertical or inferior-superior dimensions, overdentures will require at least 7mm of space when the implants are unsplinted. Overdentures made for frameworks require considerably more space -- approximately 11mm. Whereas mandibular overdentures are space-sensitive anteriorly, maxillary ones are space-sensitive posteriorly.

Among the range of patients with minimally resorbed maxillae (American College of Prosthodontists Prosthodontic Diagnostic Index (ACP PDI), Class I) to those with severely resorbed arches (ACP PDI Class IV),⁴² treatments will vary. The following hierarchy of space requirements, from least to most, exists:

1. Fixed prostheses (screw-retained).
2. Fixed prostheses (cement-retained). The space requirements for these are basically equivalent to those for removable

- prostheses with unsplinted implants (no frameworks).
3. Removable prostheses with unsplinted implants.
 4. Removable prostheses with splinted implants (frameworks).

Available or attainable restorative volume is another important factor in determining whether fixed or removable prosthetic options are viable. If a given patient presents without adequate restorative volume, increased volume may be obtained by surgically re-contouring the edentulous sites, thereby increasing the vertical dimension of occlusion. This is another critical aspect in implant treatment planning. Generally, removable prostheses require more restorative space than fixed prostheses.

The most ideal candidates for removable prostheses are those who have already reported favorable experiences with removable prostheses. However, studies indicate that just because a patient presents with a removable prosthesis, that need not mean the new prosthesis should be removable as well. In partially edentulous or edentulous arches, the transition from a removable prosthesis to an implant-retained/supported overdenture has been demonstrated to be relatively easy. The transition from a fixed to a removable prosthesis has been reported to be more difficult and may require longer periods for accommodation.⁴³

Summary of the Decision-Making Process

Fixed Prostheses

Fixed implant prostheses generally are straightforward treatment options when patient preferences, finances, and favorable anatomic factors align. Depending on the jaw shape (A/P spread) and the number of posterior teeth needed, a minimum of six well-distributed maxillary implants are recommended (with more implants generally required in areas of poor bone quality). To improve aesthetic outcomes for fixed prostheses, implants may be placed in more posterior sites. For mild/moderately resorbed maxillae, either cement- or screw-retained prostheses may be acceptable. For severely atrophic maxillae, screw-retained prostheses are currently the optimal prosthetic design, although the evolution of lab-designed CAD/CAM abutments may eventually change that. It is generally acknowledged that the most difficult of all maxillary jaws to treat are in those patients with severe resorption who will not accept removable prosthetic designs.

Removable Prostheses

Removable implant prostheses are indicated when there is a mismatch between patient preferences and other factors, e.g. when patients prefer fixed designs but either cannot afford a fixed solution or lack sufficient bone to accommodate appropriate sized implants in optimal positions. General satisfaction as well as ratings of most psychosocial and functional variables have been shown to be very high when patients compared the experience of wearing maxillary long-bar implant overdentures, both with and without palatal coverage, that were opposed by a fixed mandibular implant-supported prosthesis.²⁷ Patients who were previously unsatisfied with maxillary dentures⁴⁴ also rated maxillary long-bar overdentures significantly higher than fixed prostheses. This is distinctly different from patient reports regarding mandibular dentures.

Numerous studies have reported on the efficacy of maxillary overdentures retained and supported by six implants evenly distributed throughout the jaw.⁴⁵⁻⁴⁷ For patients with severe atrophy, bar overdentures tend to be ideal, since frameworks provide significant retention, stability, and most importantly, indirect retention for the prostheses. Such overdentures are non-rotational and tend to require minimal maintenance. For patients with mild to moderate resorption and minimal restorative space, preliminary evidence suggests that a minimum of four unsplinted implants, combined with full metal frameworks and partial palatal coverage, may provide clinically acceptable results.⁴⁸

V. Definitive Treatment Plan

Prosthesis Design

Implant dentistry is a restorative-driven service, but it is highly dependent upon surgical protocols. Implant-specific restorations must be carefully planned and designed to exact specifications prior to commencing patient treatment. If the definitive prosthesis will be fixed, clinicians must pre-determine if it will be cement- or screw-retained, as this design feature may affect implant placement relative to the locations of the screw-access openings within the restorations. Clinicians should also pre-operatively select the type of materials to be used for the prostheses (ceramic or resin) and the fabrication process (cast or CAD/CAM, including copy-milling). If the definitive prosthesis will be removable, clinicians must determine pre-operatively if the implants are to be splinted or not. Long-term prosthetic maintenance concerns are also important relative to prosthesis design because all full-arch prostheses have aftercare (post-insertion) considerations.^{41,49} These should be explained to patients at the start of the process and often may have a

significant impact on prosthetic designs. After all these determinations have been made, the clinician should review the definitive treatment plan once more with the patient.

VI. The Confirmation Letter

The confirmation letter is an important medico-legal document. It should be considered a prosthetic consent form and is a necessary component in the pre-treatment protocol described in this article. It should be signed and returned by all patients prior to beginning treatment, and it should include:

- all previous discussions
- diagnoses
- informed consent /informed refusal
- treatment options
- the definitive treatment plan, including benefits, limitations, and caveats pertaining to the chosen design
- prognoses associated with implants, natural teeth, and prostheses
- fees
- aftercare considerations (expected frequency and costs)
- patient peri-implant maintenance obligations

Clinical Relevance

This paper has described some of the differences between treatment of the maxillary and mandibular jaws. The prosthetic phase of maxillary rehabilitation (aesthetics, phonetics, prosthesis design, and fabrication) is comparatively more challenging than that for the mandible. Optimal decision-making must balance three key factors: patient preferences, finances, and anatomic conditions, including the amount of restorative space available and the question of whether or not a full or partial flange will be necessary to achieve an optimal aesthetic result. The choice of what type of provisional prosthesis will be used is another key consideration. Direct extrapolation of mandibular treatment guidelines should not be applied to maxillary situations. With careful planning and execution, maxillary treatment can result in high levels of implant success, prosthesis survival, and patient satisfaction.

References

1. Beltrán-Aguilar ED, Barker LK, Canto MT, et al. Surveillance for certain health behaviors among states and selected local areas: Behavioral risk factor surveillance system. US 2004. *Morb Mortal Wkly Rep* 2006; 55(SS-7):1-44.
2. Douglas CW, Shih A, Ostry L. Will there be a need for complete dentures in the United States in 2020? *J Prosthet Dent* 2002;87:5-8.
3. Adell R, Lekholm U, Rockler B, et al. A 15-year study of osseointegrated implants in the treatment of the edentulous jaw. *Int J Oral Surg* 1981;10:387-416.
4. Schmitt A, Zarb G. The notion of implant-supported overdentures. *J Prosthet Dent* 1998;79:60-65.
5. Awad MA, Lund JP, Dufresne E, et al. Comparing the efficacy of mandibular implant-retained overdentures and conventional dentures among middle-aged edentulous patients: Satisfaction and functional assessment. *Int J Prosthodont* 2003;16:117-122.
6. Feine JS, Carlsson GE, Awad, MA, et al. The McGill consensus statement on overdentures. *Int J Oral Maxillofac Implants* 2002;17:601-602.
7. Carpentieri J, Tarnow D. *The Mandibular Two-Implant Overdenture: First Choice Standard of Care for the Edentulous Denture Patient*. New Jersey: Montage Media, 2007.
8. Drago C, Carpentieri J. Treatment of maxillary jaws with dental implants: Guidelines for treatment. *J Prosthodont*. 2011 May 17. doi: 10.1111/j.1532-849X.2011.00717.x. [Epub ahead of print]
9. Tallgren A. The continuing reduction of the residual alveolar ridges in complete denture wearers: A mixed-longitudinal study covering 25 years. 1972. *J Prosthet Dent* 2003;89:427-435.
10. Atwood D, Coy W. Clinical, cephalometric, and densitometric study of reduction of residual ridges. *J Prosthet Dent* 1971;26(3):280-295.
11. Rocuzzo M, Aglietta M, Cordaro L. Implant loading protocols for partially edentulous maxillary posterior sites. *Int J Oral Maxillofac Implants* 2009;24 Suppl:147-157.
12. Martin W, Lewis E, Nicol A. Local risk factors for implant therapy. *Int J Oral Maxillofac Implants* 2009;24 Suppl:28-38.
13. Del Fabbro M, Testori T, Francetti L, et al. Systematic review of survival rates for implants placed in the grafted maxillary sinus. *Int J Periodontics Restorative Dent* 2004;24(6):565-577.
14. Chan MF, Närhi TO, de Baat C, et al. Treatment of the atrophic edentulous maxilla with implant-supported overdentures: A review of the literature. *Int J Prosthodont* 1998;11:7-15.
15. Razavi R, Zena RB, Khan Z, et al. Anatomic site evaluation of edentulous maxillae for dental implant placement. *J Prosthodont* 1995;4:90-94.
16. Rangert B. Biomechanics of the Brånemark system. *Aust Prosthodont J* 1995;9 Suppl:39-48.
17. Cavallaro J Jr, Greenstein B, Greenstein G. Clinical methodologies for achieving primary dental implant stability: The effects of alveolar bone density. *J Am Dent Assoc* 2009;140(11):1366-1372.
18. Graser C, Myers M, Iranpour B. Resolving esthetic and phonetic problems associated with maxillary implant-supported prostheses. A clinical report. *J Prosthet Dent* 1989;62:376-378.
19. Henry P. Future therapeutic directions for management of the edentulous predicament. *J Prosthet Dent* 1998;79:100-106.
20. Marcus PA, Joshi J, Jones JA, et al. Complete edentulism and denture use for elders in New England. *J Prosthet Dent* 1996;76:260-266.
21. Jemt T, Book K, Lindén B, et al. Failures and complications in 92 consecutively inserted overdentures supported by Brånemark implants in severely resorbed edentulous maxillae: A study from prosthetic treatment to first annual check-up. *Int J Oral Maxillofac Implants* 1992;7(2):162-167.
22. Naert I, Quirynen M, van Steenberghe D, et al. A study of 589 consecutive implants supporting complete fixed prostheses. Part II: Prosthetic aspects. *J Prosthet Dent* 1992;68(6):949-956.
23. Heydecke G, McFarland DH, Feine JS, et al. Speech with maxillary implant prostheses: Ratings of articulation. *J Dent Res* 2004;83(3):236-240.

Joseph Carpentieri, DDS & Carl Drago, DDS, MS (continued)

24. Visser A, Raghoobar GM, Meijer HJ, et al. Implant-retained maxillary overdentures on milled bar suprastructures: A 10-year follow-up of surgical and prosthetic care and aftercare. *Int J Prosthodont* 2009;22:181-192.
25. Jemt T, Book K. Prosthesis misfit and marginal bone loss in edentulous implant patients. *Int J Oral Maxillofac Implants* 1996;11(5):620-625.
26. Trieger N. Oral surgery: State of the art 1986. *NY State Dent J* 1986;52(7):26.
27. Heydecke G, Boudrias P, Awad MA, et al. Within-subject comparisons of maxillary fixed and removable implant prostheses: Patient satisfaction and choice of prosthesis. *Clin Oral Implants Res* 2003;14(1):125-130.
28. Carpentieri JR. Clinical protocol for an overdenture bar prosthesis fabricated with CAD/CAM technology. *Pract Proced Aesthet Dent* 2004;16(10):755-757.
29. Carter L, Farman AG, Geist J, et al. American Academy of Oral and Maxillofacial Radiology executive opinion statement on performing and interpreting diagnostic cone beam computed tomography. *J Oral Maxillofac Surg* 2008;106(4):561-562.
30. Block MS, Mercante DE, Lirette D, et al. Prospective evaluation of immediate and delayed provisional single tooth restorations. *J Oral Maxillofac Surg* 2009 Nov;67(11 Suppl):89-107.
31. Greenstein G, Cavallaro J Jr. Serial extraction protocol: Transitioning a hopeless dentition to a full-arch reconstruction. *Compend Contin Educ Dent* 2008;29(9):526-534.
32. Grunder U. Immediate functional loading of immediate implants in edentulous arches: Two-year results. *Int J Periodontics Restorative Dent* 2001;21(6):545-551.
33. Balshi SF, Wolfinger GJ, Balshi TJ. A prospective study of immediate functional loading, following the Teeth in a Day protocol: A case series of 55 consecutive edentulous maxillas. *Clin Implant Dent Relat Res* 2005;7:24-31.
34. Galluci GO, Bernard JP, Bertosa M, et al. Immediate loading with fixed screw provisional restorations in edentulous jaws: The pick-up technique. *Int J Oral Maxillofac Implants* 2004;15:278-284.
35. Malo P, Rangert B, Nobre M. All-on-4 immediate-function concept with Brånemark System implants for completely edentulous maxillae: A 1-year retrospective clinical study. *Clin Implant Dent Relat Res* 2005;7 Suppl 1:S888-894.
36. Östman PO, Hellman M, Sennerby L. Direct implant loading in the edentulous maxilla using a bone density-adapted surgical protocol and primary implant stability criteria for inclusion. *Clin Implant Dent Relat Res* 2005;7 Suppl 1:S60-69.
37. Van Steenberghe D, Glauser R, Blomback U, et al. A computed tomographic scan-derived customized surgical template and fixed prosthesis for flapless surgery and immediate loading of implants in fully edentulous maxillae: A prospective multicenter study. *Clin Implant Dent Relat Res* 2005;7 Suppl 1:S111-120.
38. Capelli M, Zuffetti F, Del Fabbro M, et al. Immediate rehabilitation of the completely edentulous jaw with fixed prosthesis supported by either upright or tilted implants. A multicenter clinical study. *Int J Oral Maxillofac Implants* 2007;22:639-644.
39. Bergkvist G, Nilner K, Sahlholm S, et al. Immediate loading of implants in the edentulous maxilla: Use of an interim fixed prosthesis followed by a permanent fixed prosthesis: A 32 month prospective radiological and clinical study. *Clin Implant Dent Relat Res* 2009;11:1-10.
40. Tang L, Lund JP, Taché R, et al. A within-subject comparison of mandibular long-bar and hybrid implant-supported prostheses: Psychometric evaluation and patient preference. *J Dent Res* 1997;76(10):1675-1683.
41. Brånemark PI, Svensson B, Steenberghe D. Ten-year survival rates of fixed prostheses on four or six implants ad modum Brånemark in full edentulism. *Clin Oral Impl Res* 1995;6:227-231.
42. McGarry T, Nimmo A, Skiba J, et al. Classification system for complete edentulism. *J Prosthodont* 1999;8:27-39.
43. Jemt T. Implant treatment in elderly patients. *Int J Prosthodont* 1993;6:456-461.
44. de Albuquerque Júnior RF, Lund JP, Tang L, et al. Within-subject comparison of maxillary long-bar implant-retained prostheses with and without palatal coverage: Patient-based outcomes. *Clin Oral Implants Res* 2000;11(6):555-565.
45. Desjardins R. Prosthesis design for osseointegrated implants in the edentulous maxilla. *Int J Oral Maxillofac Implants* 1992;7:311-320.
46. Krämer A, Weber H, Benzing U. Implant and prosthetic treatment of the edentulous maxilla using a bar-supported prosthesis. *Int J Oral Maxillofac Implants* 1992;7(2):251-255.
47. Eckert SE, Carr AB. Implant-retained maxillary overdentures. *Dent Clin North Am* 2004;48(3):585-601.
48. Cavallaro JS Jr, Tarnow DP. Unsplinted implants retaining maxillary overdentures with partial palatal coverage: Report of 5 consecutive cases. *Int J Oral Maxillofac Implants* 2007;22:808-814.
49. Attard NJ, Zarb GA, Laporte A. Long-term treatment costs associated with implant-supported mandibular prostheses in edentulous patients. *Int J Prosthodont* 2005;18:117-123.

Joseph Carpentieri, DDS



Dr. Carpentieri received his dental degree from Baltimore College of Dental Surgery at the University of Maryland and his Certificate in Prosthodontics from Albert Einstein College of Medicine, Montefiore Medical Center in the Bronx, New York. He completed a four-year surgical fellowship at the Department of Periodontology and Implant Dentistry at New York University College of Dentistry. Currently, he is an associate professor at Columbia University College of Dental Medicine. Dr. Carpentieri maintains a private practice limited to prosthodontics in White Plains, New York.

Carl J. Drago, DDS, MS



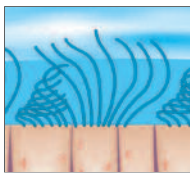
Dr. Drago received his dental degree from Ohio State University College of Dentistry in Columbus, Ohio, and a Masters Degree from the University of Texas Graduate School of Biomedical Sciences at San Antonio, Texas. Dr. Drago is a Diplomate of the American Board of Prosthodontics and was re-certified in 2008. He is a Fellow in both the American College of Prosthodontists and the American College of Dentists and an associate Fellow in the Greater New York Academy of Prosthodontics. He lectures both nationally and internationally, has published over 65 papers on multiple subjects, written three textbooks on dental implants, and he is also the Clinical Science section editor for the *Journal of Prosthodontics*. Dr. Drago is currently Clinic Director, EON Clinics, Waukesha, Wisconsin.

[†]The contributing clinicians have financial relationships with BIOMET 3i LLC resulting from speaking engagements, consulting engagements, and other retained services.

Sinus

Maxillary sinus surgery: Anatomy and advanced diagnostic imaging

Tiziano Testori, MD, DDS[†]



No treatment plan for the posterior maxilla can fail to consider the status of the maxillary sinus. If pneumatization of the sinus or alveolar bone resorption has occurred, then bone grafting or sinus elevation may be necessary to enable implant-supported rehabilitation. Anatomic features including the Schneiderian membrane, the major arteries and nerves, and any bony septa optimally should be three-dimensionally rendered with advanced diagnostic imaging technologies such as computed tomography (CT). A determination can then be made as to whether alternatives to sinus elevation may be considered. If sinus elevation is inevitable, it is essential to have an excellent understanding of the sinus anatomy, which is briefly outlined in this article.

Key Words: sinus anatomy, maxilla, diagnostic imagery

Introduction

In developing any treatment plan for the maxilla that includes the posterior regions, the status of the maxillary sinus must be carefully considered. Pneumatization of the sinus may limit the amount of residual bone. Given the tendency of the alveolar ridge to progressively resorb after tooth loss and the typically poorer quality of posterior maxillary bone, rehabilitation of this area with implant-supported fixed prostheses has traditionally been challenging.

Clinicians initially tried to solve the problem of insufficient posterior bone support by using prostheses with distal extensions supported by implants placed anteriorly or by combining long implants in the anterior with short posterior implants. However, by the late 1970s, Tatum¹ and Boyne² were reporting on an alternative: elevation of the maxillary sinus in order to better accommodate placement of

endosseous implants. Since then, numerous approaches to maxillary sinus elevation have developed, and a substantial body of research has demonstrated the procedure to be predictably successful.³ At the same time, other alternatives have also developed, including the use of reduced-length implants with roughened surfaces or tilted implants inserted in a variety of ways.

This article briefly reviews the role of computed tomography (CT) when sinus-augmentation surgery is being considered.

The Role of CT in Sinus Augmentation

When the alveolar process has resorbed significantly and sufficient bone to accommodate implants appears to be unavailable, diagnostic imaging plays a vital role, providing reliable and necessary information.^{4,5} CT offers considerable advantages compared with traditional diagnostics (orthopantomography,

Fig. 1.

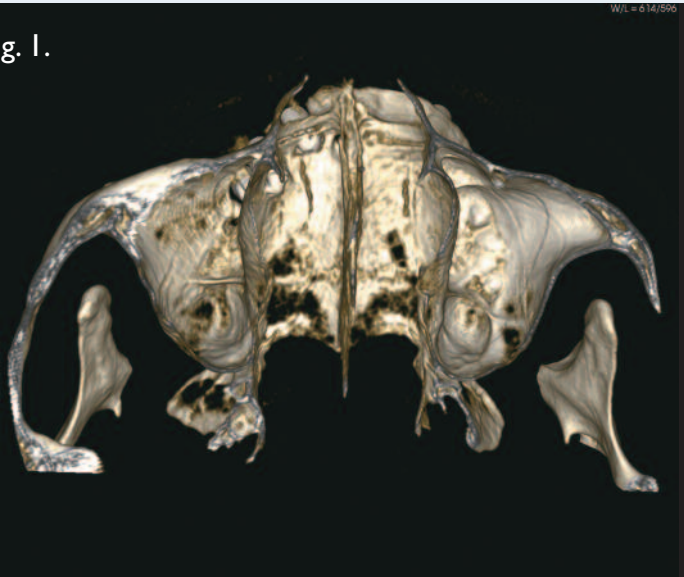

Fig. 2.

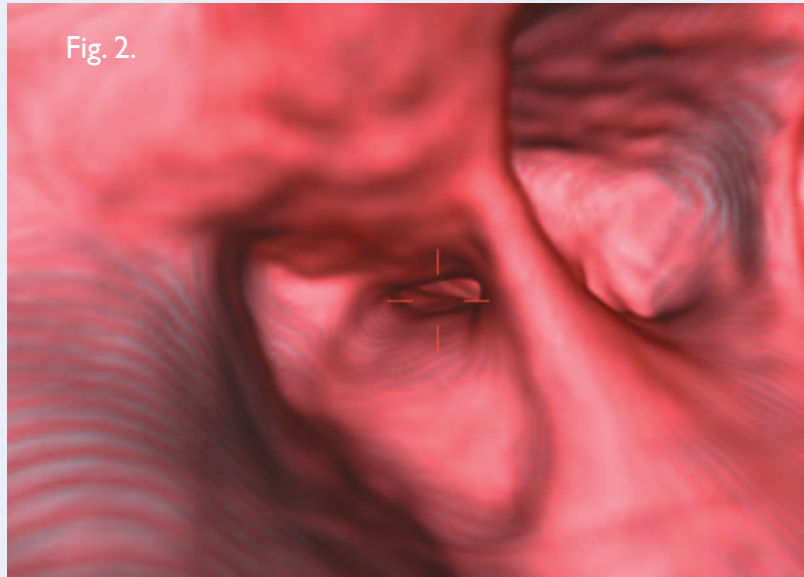
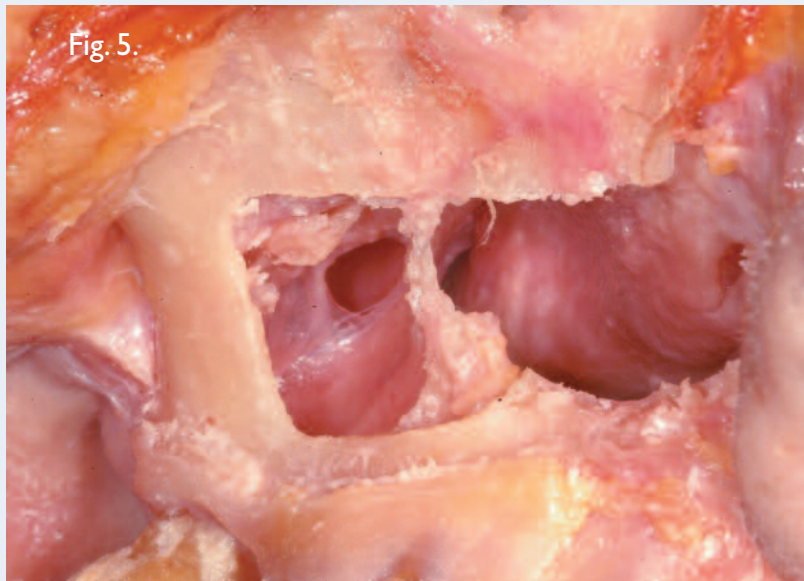


Fig. 4.

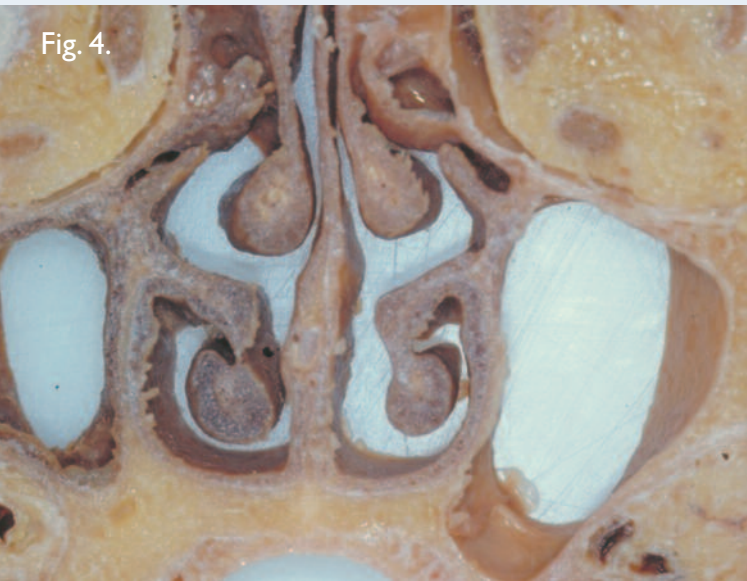

Fig. 5.



intraoral radiographs). For complex dental operations, CT must be considered an essential presurgical diagnostic method (Figs. 1-3).⁶⁻⁸

With three-dimensional reconstructions based on CT scan data, morpho-volumetric analysis of the planned surgical site becomes relatively simple, and the available densitometric information ensures much higher diagnostic confidence compared with conventional radiologic investigation. Electronic reconstructions are now available in various rendering modes that synthesize an enormous amount of information, contained

in hundreds of axial images. In addition to being immediate and diagnostically exhaustive, these images can be easily interpreted by operators.

Combining the scan data with a computer-guided surgical system such as the Tapered Navigator® Kit (BIOMET 3i) for CT guided surgery may make it possible to place implants despite the anatomical limitations. CT guidance technology allows clinicians to measure with great precision the locations of anatomic structures and the dimensions of underlying bone. Bone densities can also be easily identified, and an accurate surgical guide with

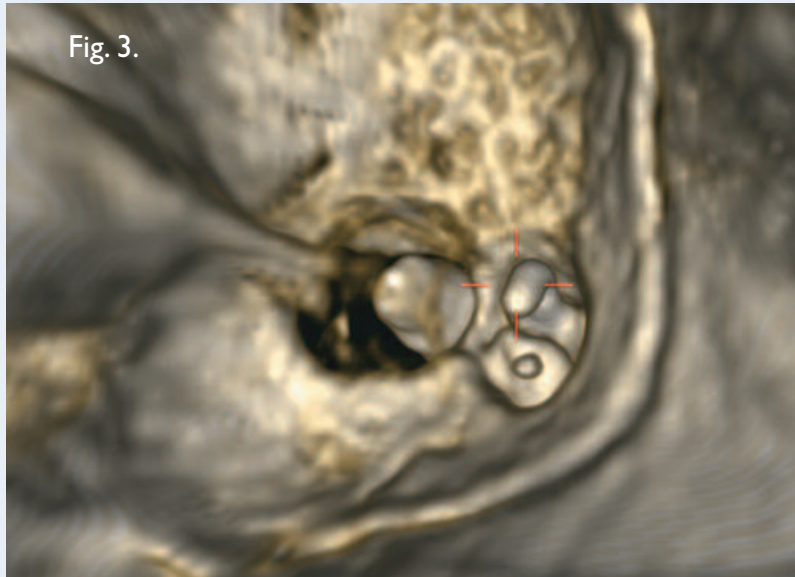


Fig. 1. High definition 3D reconstruction of the maxillary bone.

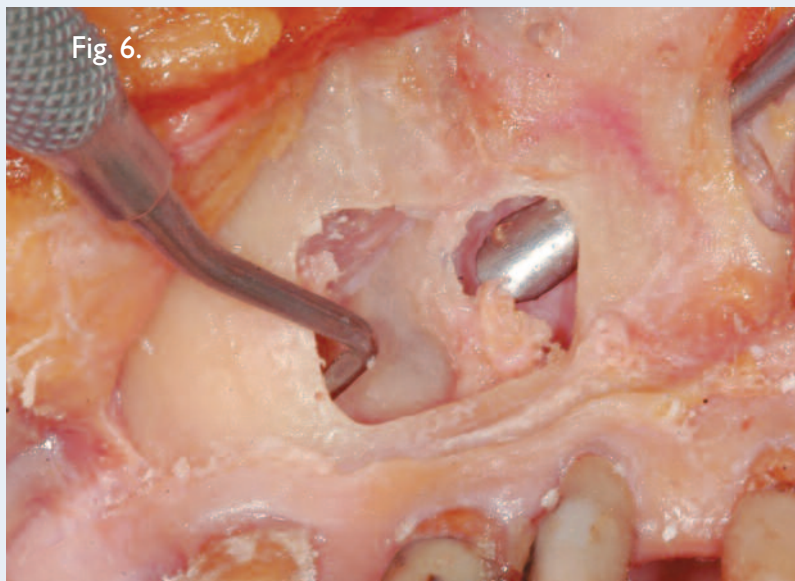
Fig. 2. Virtual endoscopy with VRT superimposition of soft tissues can be used to check patency.

Fig. 3. Virtual endoscopy used to analyze the tooth positions with respect to the maxillary sinus floor.

Fig. 4. Frontal section of the maxillary sinuses. Hyperpneumatization of the left sinus and atrophy of the alveolar ridge subsequent to tooth loss is evident.

Fig. 5. Relationship between the nasal cavity and the maxillary sinus.

Fig. 6. The instrument enters from the pyriform opening and reaches the medial wall of the sinus (the lateral wall of the nasal cavity).



precise surgical instrumentation can be fabricated. The use of these combined tools sometimes enables placement of implants when the bone under the maxillary sinus is minimal.

If a sinus elevation is unavoidable, a variety of anatomical factors may influence the design of the lateral window and the choice of graft material. Information on bone density, bone cortical walls, and bone resorption in the alveolar processes is important for planning functionally and aesthetically optimal prosthetic treatment. Information on associated orosinus pathologies is also important.

Determining the position and patency of the maxillary sinus ostium is essential when planning sinus-elevation procedures. Of particular importance is the integrity of the ostio-meatal complex, the morpho-functional unit used for drainage and aeration of the anterior ethmoidal cells, the maxillary sinuses, and the frontal sinuses. CT scanning allows for precise evaluation of its numerous components, revealing any irregularities in development (e.g. bulla conche, septum deviation, or inflammation involving the maxillary sinus ostium). Respecting the structure of the ostium is essential for a successful operation.

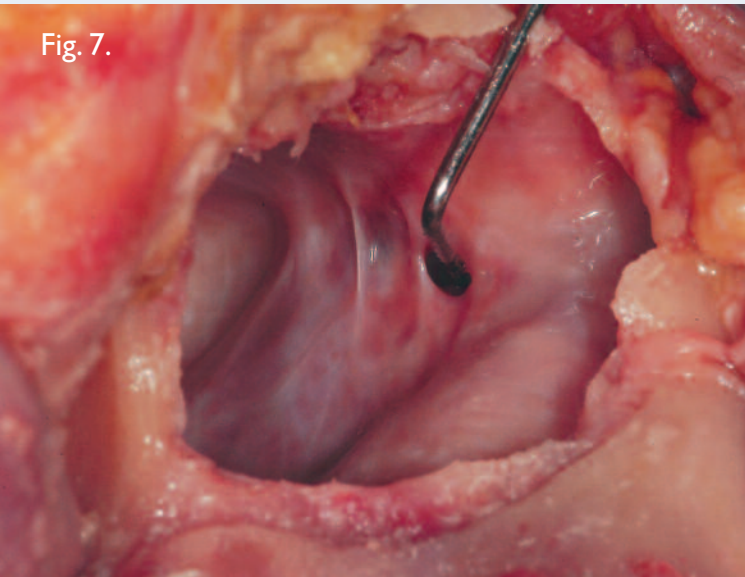


Fig. 7.

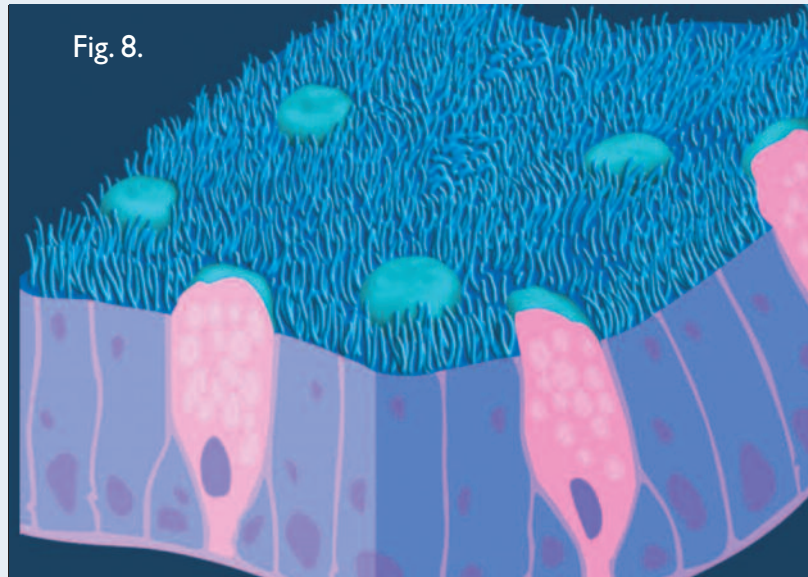


Fig. 8.

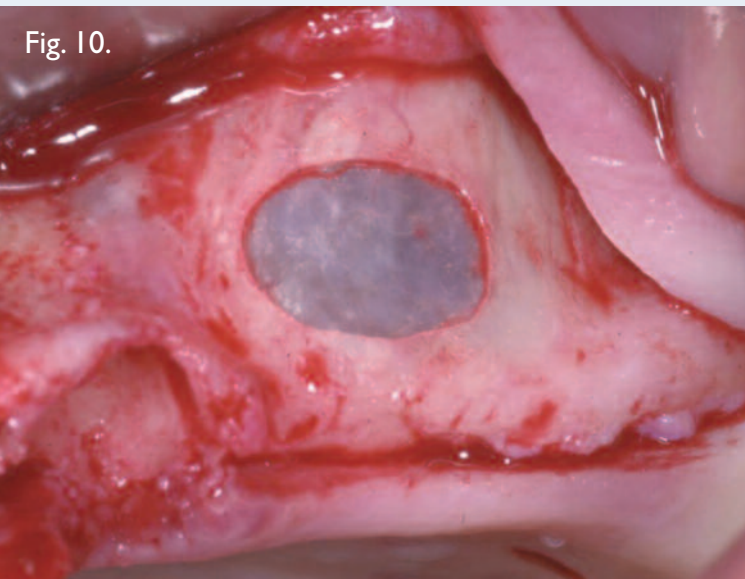


Fig. 10.

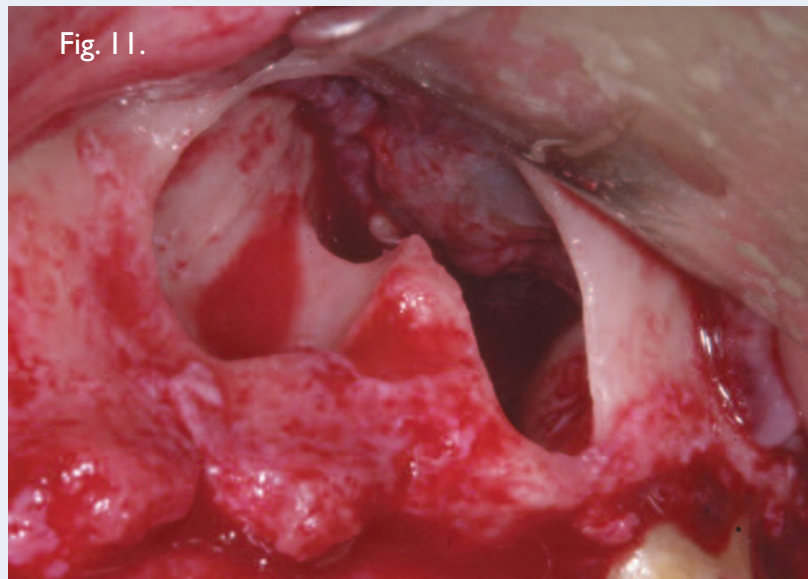


Fig. 11.

Overview of the Sinus Anatomy

All the paranasal sinuses occupying the maxillary bone humidify and warm the inhaled air. They also thermally insulate the upper nerve centers, protect the skull base from trauma, influence phonation by acting as an indirect resonance box, and contribute to reducing the weight of the facial bones.^{9,10} The largest of the paranasal air cavities, the maxillary sinus includes a medial wall that separates the maxillary sinus from the nasal cavity, a posterior wall facing the maxillary tuberosity, a mesio-vestibular wall containing the neurovascular bundle, an upper wall constituting the

orbit floor; and a lower wall next to the alveolar process that is the bottom of the maxillary sinus itself (Figs. 4 and 5).¹¹ The maxillary sinus communicates with the homolateral nasal fossa by means of a natural ostium located postero-superiorly on the medial surface (Figs. 6 and 7). In adults with a full set of teeth, the maxillary sinus floor is the strongest of the bone walls surrounding the cavity. However, as aging occurs, the sinus floor tends to resorb and form dehiscences around the roots. The root ends may jut into the cavity, covered only by the Schneiderian membrane and a small

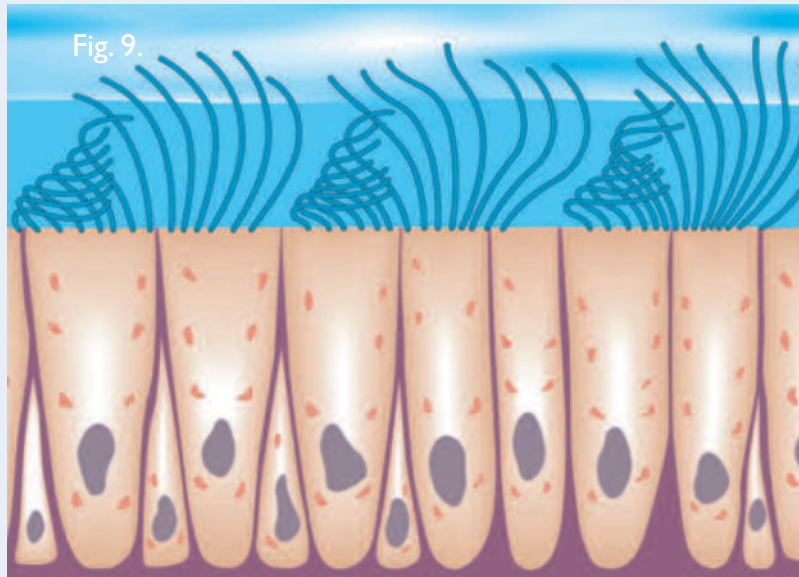


Fig. 7. The foramen of the sinus ostium is normally a 6mm by 3.5mm oval.

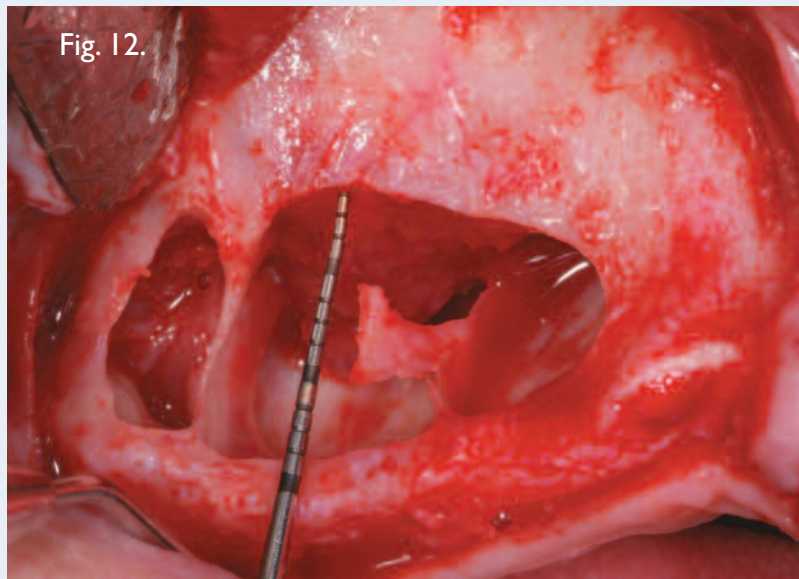
Fig. 8. Diagram of the Schneiderian mucosa with various cellular components.

Fig. 9. Diagram of the ciliated epithelium, propellant for sinus secretions.

Fig. 10. A thin sinus membrane.

Fig. 11. Underwood septa inside the maxillary sinus.

Fig. 12. Another view of the Underwood septa.



bone cortex flap (which in turn may be missing). Extreme care must be taken to avoid tearing the membrane when separating it from such exposed apices.

The mesio-vestibular and medial bone walls are the ones most often involved in maxillary sinus surgery. An accessory ostium may sometimes be found on the medial wall. When this occurs, it should be identified before any maxillary sinus-elevation procedure is performed, to avoid detaching the mucosa up to this point.

The Sinus Membrane

The Schneiderian (mucous) membrane lines the inner walls of the sinus and in turn is covered by pseudo-stratified columnar ciliated epithelium (Figs. 8-10). Serum-mucosa glands are located in the lamina directly underneath, especially next to the ostium opening. Normally the thickness of the Schneiderian membrane varies from 0.13mm to 0.5mm. However; inflammation or allergic phenomena may cause it to thicken, either generally or locally (in streaks). In such cases, it may be necessary for an otolaryngologist to

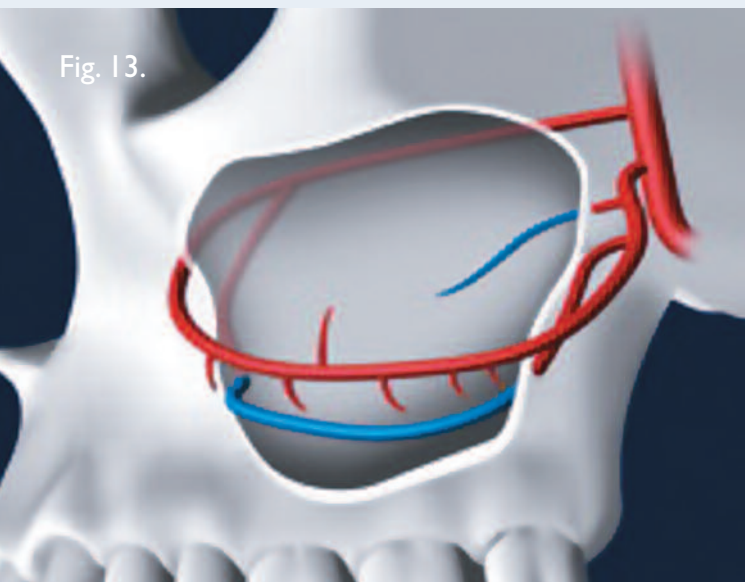


Fig. 13.

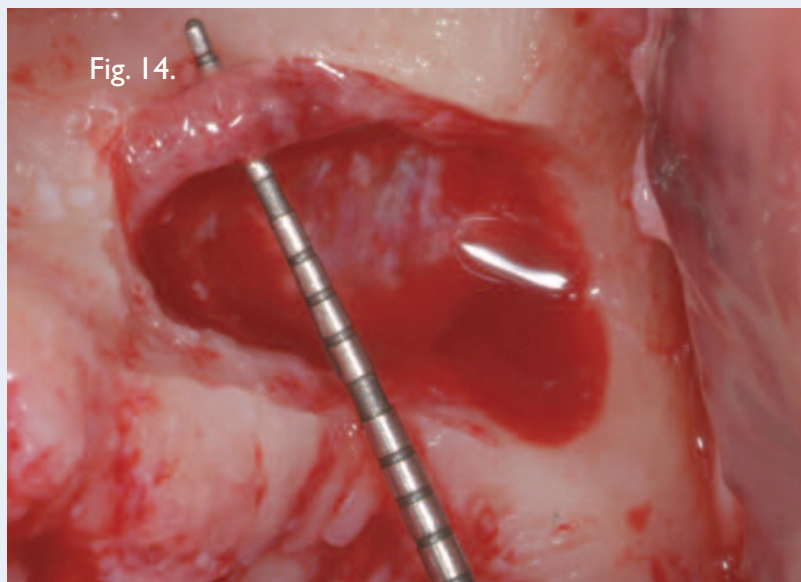


Fig. 14.

restore the sinus to a physiologic state before a sinus-lift operation can be carried out.

Progressive Change, Edentulism, and Bone Resorption

In cases of maxillary edentulism, progressive resorption of the alveolar ridge may reduce the bone to a thickness of less than 1 mm. Several causes may contribute to this phenomenon. Teeth and the masticatory loads they apply stimulate the alveolar bone and limit its resorption. Immediately after the avulsion of a tooth, significant bone-modeling typically occurs. Vertical bone loss later tends to stabilize, averaging about 0.1 mm/year, though large variations can be found among individuals. However, hormonal imbalances, metabolic factors, inflammation, and certain systemic pathologies can cause the bone resorption to accelerate again. Age and gender may also influence bone loss.

The sinus floor tends to lower craniocaudally as the alveolar ridge is resorbed in the opposed direction. It is the lack of vertical posterior maxillary bone that often necessitates the use of bone grafts or sinus-lifting procedures prior to implant rehabilitation.

Progressive resorption of the posterior maxillary edentulous ridge follows a well-defined path that differs from that of the anterior regions and includes repeatable, predictable morphologic changes. Cawood and Howell's system for classifying the degrees of atrophy based on the morphologic

differences in the residual ridge¹² is extremely useful for presurgical diagnostic assessment, as the ridge appearance is connected to the horizontal and vertical size of bone available for implants.

Bony Septa

Inside the maxillary sinus, bony septa originating in the sinus floor are often found (Figs. 11 and 12). Called Underwood septa, they may divide the back part of the sinus into multiple compartments known as posterior recesses. They may even occasionally reach from the base to the upper sinus wall, creating two sinuses.¹³ Estimates of the prevalence of such septa have ranged from 16 to 58%.¹⁴⁻¹⁷

The formation of Underwood septa may be linked to the fact that teeth are lost at different times. The edentulous areas may resorb in a manner that results in a difference in level between the two adjacent portions of the sinus floor. It is thought that a bony septum may form in the area between the two regressing areas in order to transfer masticatory loads optimally. After the complete loss of teeth, the septa sometimes gradually disappear.¹⁸

A tridimensional x-ray diagnosis of septa presence is important for planning the size, shape, and position of the antrostomy in maxillary sinus elevation and later separating the sinus membrane from the septa.

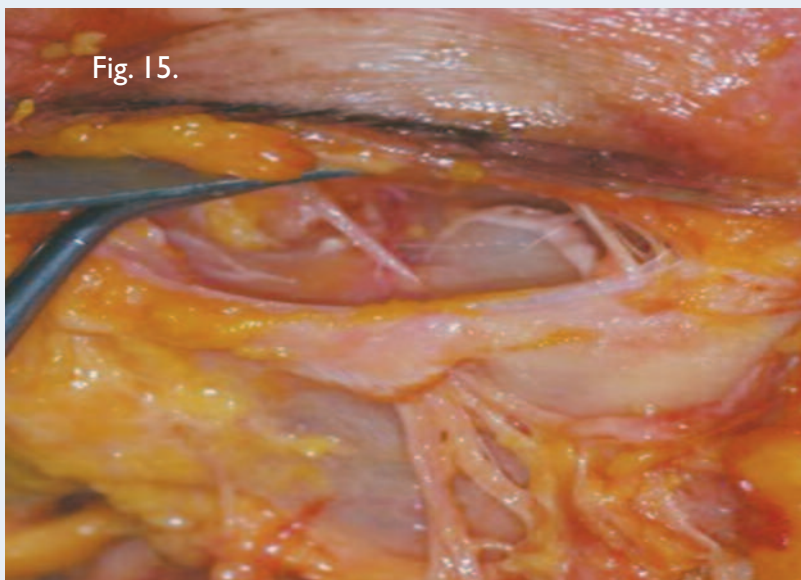

Fig. 15.

Fig. 13. Vascular system of the maxillary sinus.

Fig. 14. The diameter of this alveolar antral artery, detected during left sinus-floor augmentation, was nearly 3mm.

Fig. 15. After emerging from the infraorbital foramen, the infraorbital nerve seen in this cadaver dissection splits into smaller branches.

Vascularization

Three arteries supply blood to the maxillary sinus: the infraorbital artery, the posterior lateral nasal artery, and the posterior superior alveolar artery (Figs. 13 and 14). While their presence should be investigated to avoid hemorrhages during sinus-grafting surgery, severe hemorrhages tend to be rare, as the main arteries do not run inside the surgical area.¹⁹

If small vessels located in the exposed Schneiderian membrane are broken, it is better to allow hemostasis to occur naturally. Applying light pressure with a gauze may be effective, however; whereas an electrocoagulator may cause membrane necrosis.

Innervation

Innervation of the maxillary sinus originates directly from the maxillary nerve, the second branch of the fifth cranial nerve. With its posterior middle and superior alveolar branches, it innervates the posterior sinus floor together with the molar and premolar teeth. The anterior superior alveolar branch reaches the anterior sinus wall and the superior dental plexus, running below the Schneiderian membrane.

Some branches starting in the infraorbital nerve branch out from the trunk before exiting the infraorbital foramen (Fig. 15). They then innervate the maxillary sinus medial wall. Branches of the pterygopalatine ganglion and the sphenopalatine ganglion also innervate the sinus mucosa.

Clinical Relevance

Any clinician treating the posterior maxilla must have a firm understanding of the anatomy of the maxillary sinus. The use of CT scanning prior to treatment of patients with significant posterior maxillary resorption can provide invaluable information about the precise status of the patient's bone and other significant structures, making it easier to choose among treatments including sinus-floor elevation.

References

1. Tatum OH. Maxillary sinus grafting for endosseous implants. Lecture, Alabama Implant Study Group, Annual Meeting, Birmingham AL, USA, 1977.
2. Boyne PJ, James RA. Grafting of the maxillary sinus floor with autogenous marrow and bone. *J Oral Surg* 1980;38:613-616.
3. Del Fabbro M, Francetti L, Taschieri S, et al. Systematic review of the literature on maxillary sinus augmentation associated with implantation procedures. In: Testori T, Del Fabbro M, Weinstein R, Wallace S (eds). *Maxillary Sinus Surgery and Alternatives in Treatment*. London: Quintessence, 2009:326-341.
4. Dula K, Buser D, Porcellini B, et al. Computed tomography/oral implantology (I). Dental CT: A program for the computed tomographic imaging of the jaws: The principles and exposure technic. *Schweiz Monatsschr Zahnmed* 1994;104:450-459.
5. Dula K, Buser D. Computed tomography/oral implantology. Dental CT: A program for the computed tomographic imaging of the jaws. The indications for preimplantological clarification. *Schweiz Monatsschr Zahnmed* 1996;106:550-563.
6. Schom C, Engelke W, Kopka L, et al. Indications for dental-CT. Case reports. *Aktuelle Radiol* 1996;6:314-324.
7. Testori T, Sacerdoti S, Barenghi A, et al. La tomografia assiale computerizzata nella moderna implantologia: Reali vantaggi per una corretta programmazione chirurgico-protetico; dose assorbita dal paziente. *Ital J Osseointegration* 1993;1:19-28.

Tiziano Testori, MD, DDS (continued)

8. Belloni GM, Testori T, Francetti L, et al. TC spirale in implantologia. Valutazione della dose radiante assorbita. *Dental Cadmos* 1999;2:55-58.
9. Blanton PL, Biggs NL. Eighteen hundred years of controversy: The paranasal sinuses. *Am J Anat* 1969;124:135-148.
10. Ritter FN, Lee D. *The Paranasal Sinuses, Anatomy and Surgical Technique*. St. Louis: The Mosby Company, 1978:6-16.
11. McGowan DA, Baxter PW, James J. *The Maxillary Sinus and Its Dental Implications*. Oxford: Wright, Butterworth-Heinemann Ltd., 1993:1-125.
12. Cawood JI, Howell RA. Reconstructive preprosthetic surgery. I. Anatomical considerations. *Int J Oral Maxillofac Surg* 1988;17:233-236.
13. Miles AEW. The maxillary antrum. *Br Dent J* 1973;134:61-63.
14. Underwood AS. An inquiry into the anatomy and pathology of the maxillary sinus. *J Anatomical Physiol* 1910;44:354-369.
15. Jensen OT, Greer R. Immediate placement of osseointegrating implants into the maxillary sinus augmented with mineralized cancellous allograft and Gore-Tex: Second-stage surgical and histologic findings. In: Laney WR, Tolman DE (eds). *Tissue Integration in Oral Orthopedic and Maxillofacial Reconstruction*. Chicago: Quintessence, 1992:321-333.
16. Ulm CWP, Solar G, Krennmair G, et al. Incidence and suggested surgical management of septa in sinus lift procedures. *Int J Oral Maxillofac Implants* 1995;10:462-465.
17. Kim MJ, Jung UW, Kim CS, et al. Maxillary sinus septa: prevalence, height, location, and morphology. A reformatted computed tomography scan analysis. *J Periodontol* 2006;77(5):903-908.
18. van den Bergh JPA, ten Bruggenkate CM, Disch FJM, et al. Anatomical aspects of sinus floor elevations. *Clin Oral Implants Res* 2000;11:256-265.
19. Testori T, Rosano G, Taschieri S, et al. Ligation of an usually large vessel during maxillary sinus floor augmentation. A case report. *Eur J Oral Implantol* 2010;3(3):255-258.

Tiziano Testori, DDS, MD



Dr. Testori is Assistant Clinical Professor and Head of the Section of Implant Dentistry and Oral Rehabilitation, Department of Odontology, at the University of Milan, I.R.C.C.S., Galeazzi Institute (Chairman Prof. R.L. Weinstein), in Milan, Italy. He has authored numerous publications and a textbook on immediate loading. He maintains a private practice specializing in implant dentistry in Como, Italy. His website is www.implantologiaitalia.it.

[†]The contributing clinician has a financial relationship with BIOMET 3i LLC resulting from speaking engagements, consulting engagements, and other retained services.



Maxillary Sinus Surgery and Alternatives in Treatment was written by Dr. Testori in collaboration with Drs. Massimo Del Fabbro, Robert Weinstein, and Stephen Wallace.


Inspired by an idea originating at the Consensus Conference on Maxillary Sinus of the Italian Society of Oral Surgery in 2001, the authors created a new, up-to-date textbook that brings together the most recent scientific discoveries and innovative clinical protocols for maxillary sinus augmentation as well as possible alternatives to these techniques. The textbook begins with anatomy, otorhinolaryngologic implications, and bone healing, then progresses to diagnostic, surgical, and patient-monitoring phases. It is a valuable resource for both students and professional clinical experts.

This book (380 pp; 409 mostly color illus; ISBN 978-1-85097-170-2 ©2009) may be ordered from Quintessence Publishing Co Inc. http://www.quintpub.com/display_detail.php3?psku=B9032



The OSSEOTITE® 2 Certain® Implant: A one-year interim report on a prospective clinical and radiographic study

Pär-Olov Östman, DDS, PhD†



Although high success rates have been reported for implants placed with immediate-loading procedures, this approach places high demands on clinicians. To meet those demands, surgical methods can no longer be standardized. To test the hypothesis that experienced surgeons can obtain the best primary stability and clinical results by choosing a combination of implants and drilling procedures that suits the bone conditions at the implant sites, this prospective clinical study of OSSEOTITE 2 Certain Implants was designed. In 39 patients, 78 implants were placed; 69 of them (88%) were immediately loaded. After one year, the overall cumulative implant-survival rate was 100%.

Key Words: OSSEOTITE 2 Certain Implant, parallel-walled, immediate loading, dental implants

Introduction

Firm initial stability is regarded as one determinant of success for dental implants placed with two-stage protocols¹ and may be even more important when using an immediate-loading protocol. Meta-analyses of clinical follow-up studies of partially edentulous and edentulous patients treated with implants have shown that an implant-survival rate of 95% can be expected over a five-year period.^{2,3} Studies show higher failure rates in soft bone and for short implants, which indicates that a certain degree of implant stability is required for successful integration and function during loading.⁴ The degree of primary stability at implant placement depends on factors related to the properties of the bone, the implant design, and the surgical technique used.⁵ Secondary implant stability depends on the tissue response to the surgery and the implant material. Implant surface topography may also be an important factor for proper integration.

Materials and Methods

Study patients and preliminary inclusion criteria

The clinical work was conducted by one investigator at a single study center. Patients needing implant-supported prostheses were selected for study inclusion based on the following preliminary criteria: presence of residual bone sufficient to support at least an 8.5mm length implant, absence of infection at the implant site, and patient willingness to sign a consent form. Exclusion criteria consisted of general contraindications for oral surgery and individuals less than 18 years of age. All patients invited to participate were thoroughly informed about all study procedures and understood that the final decision for enrollment would be based on additional inclusion criteria assessed at the implant-placement surgery.

Study implants

OSSEOTITE 2 Certain Implants (BIOMET 3i) are available in lengths of 8.5mm to 15.0mm and diameters of 3.25mm,

4.0mm, 5.0mm, and 6.0mm (Fig. 1). Compared to the earlier OSSEOTITE® Certain® Implants, the 3.25mm and 4.0mm diameter OSSEOTITE 2 Certain Implants have a longer straight-wall section, a reduced apical taper, and modified cutting flutes. The 5.0mm and 6.0mm OSSEOTITE 2 Certain Implants incorporate these design changes and also have the same thread design as BIOMET 3i Tapered Implants, with a narrower thread pattern, a 35-degree thread angle, and a 0.8mm thread pitch (Fig. 2).

For the present study, only 4.0mm and 5.0mm diameter OSSEOTITE 2 Certain Implants were used.

OSSEOTITE 2 Certain Implants are manufactured from commercially pure titanium and are dual-acid-etched (DAE®) to impart the OSSEOTITE Surface from the apex to the implant seating surface. The OSSEOTITE Surface is characterized by one- to three-micron peak-to-peak irregularities. This complex micron-scale topography has been theorized to aid in blood-clot retention, platelet activation, and *de novo* bone interdigitation. In order to adequately view these micron-scale irregularities, the implants had to be analyzed using high magnification ($\geq 2000\times$) scanning electron microscopy (SEM).

In addition to characterization through SEM, interferometry techniques were utilized to explore the surface roughness on which the OSSEOTITE Surface features are present. This analysis was conducted at approximately 312x magnification using a 3D surface profiler and optical interferometer (MicroXAM EX-100, KLA-Tencor Development Series, KLA-Tencor Corporation, Milpitas, California, USA). Two measurements, S_a (average height deviation, a height-descriptive parameter) and S_{dr} (developed surface area, a hybrid parameter that includes information from spatial as well as height distributions) were analyzed. The measurements were made at BIOMET 3i Headquarters in Palm Beach Gardens, Florida, USA (Fig. 3).

Implant-placement surgery and final inclusion criteria

Patients were administered oral antibiotics and sedatives one hour prior to surgery. At 68 of the implant-placement sites (87%), a mid-crestal incision was made, and a mucosal flap was reflected. Both the aesthetic and biomechanical aspects of the site and alveolar ridge were carefully evaluated to determine the optimal implant position. At

10 sites (13%), implant placement followed immediately after extraction (13%), and no flap was reflected.




Fig. 1. The study implants are OSSEOTITE 2 Certain Parallel Walled Implants with the OSSEOTITE Surface extending from the apex to the implant seating surface. Implants are available in 8.5mm to 15.0mm lengths and 3.25mm, 4.0mm, 5.0mm, and 6.0mm diameters.

At all sites, bone quality and quantity were assessed using Lekholm and Zarb's criteria⁵ (Table 1). Implants were placed according to a diagnostic drilling protocol,⁶ meaning that selection of the final drill size was based on bone quality to increase initial primary stability. In Type I bone, the final drill size was 3.25mm (4.0mm implant diameter) and 4.25mm (5.0mm implant diameter). In Types II, III, and IV bone, the final diameter drill used to prepare the osteotomy was reduced in order to gain as much immediate bone-to-implant contact (IBIC) as possible (Fig. 4). A countersink drill was not used. Insertion torques were measured with an Elcomed drill unit (W&H Dentalwerk GmbH, Bürmoos, Austria). After seating of the implant, implant stability was assessed using Resonance Frequency Analysis (RFA) performed with an Osstell ISQ (Osstell AB, Göteborg, Sweden).

Had any implants been rotationally unstable, they would have been treated with a two-stage protocol, and those patients would have been dropped from the study. Otherwise, if a minimum insertion torque of 30Ncm was recorded before the final seating of the implant, and the implant stability quotient (ISQ) was 55 or higher, then the implant was immediately loaded. The only exceptions were single units placed in the molar region; all of these implants were placed using a one-stage protocol.

Of the 39 patients initially invited to participate in the study, all met the final inclusion criteria. A total of 78 implants supporting 39 fixed prostheses were placed

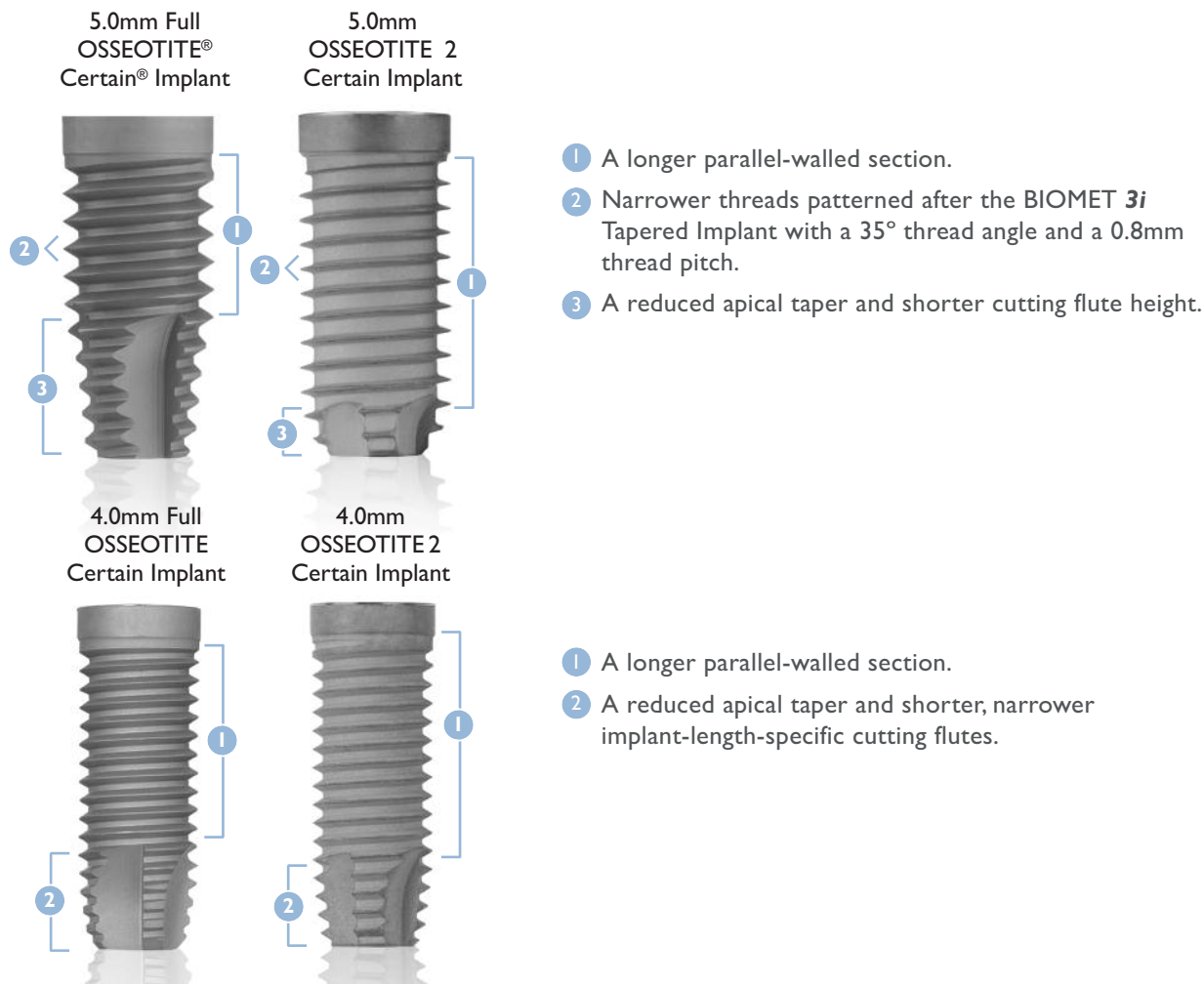


Fig. 2. The design of the 3.25mm and 4.0mm diameter OSSEOTITE 2 Certain Implants changed slightly from the existing OSSEOTITE Certain Parallel Walled Implants in that there is a longer straight walled section, a reduced apical taper, and modified cutting flutes. Additionally, the design change for the 5.0mm and 6.0mm diameter implants includes a narrower thread pattern, 35° thread angle, and a 0.8mm thread pitch. The thread design is the same as on the present tapered implants from BIOMET 3i.

(Tables 2 and 3). Sixty-nine of the implants were immediately loaded, while nine implants were loaded following a healing period. For the first ten days after implant placement, patients were prescribed antibiotics, twice-daily mouth rinsing with chlorhexidine (0.1%), and a soft diet.

Prosthetic Procedures

Immediately loaded implants were treated as follows: Before adaptation and suturing of the mucosal flaps, either PreFormance® Posts (BIOMET 3i), PreFormance Temporary Cylinders (BIOMET 3i) or Low Profile Abutments with QuickBridge® Provisional Components (BIOMET 3i) were placed to support the provisional restorations. Cantilevers were allowed in the study but were restricted to 5.0mm or less.




Fig. 3. SEM of the OSSEOTITE 2 Certain Implant, which is made of commercially pure (CP) Grade IV Titanium and is dual-acid-etched (DAE).

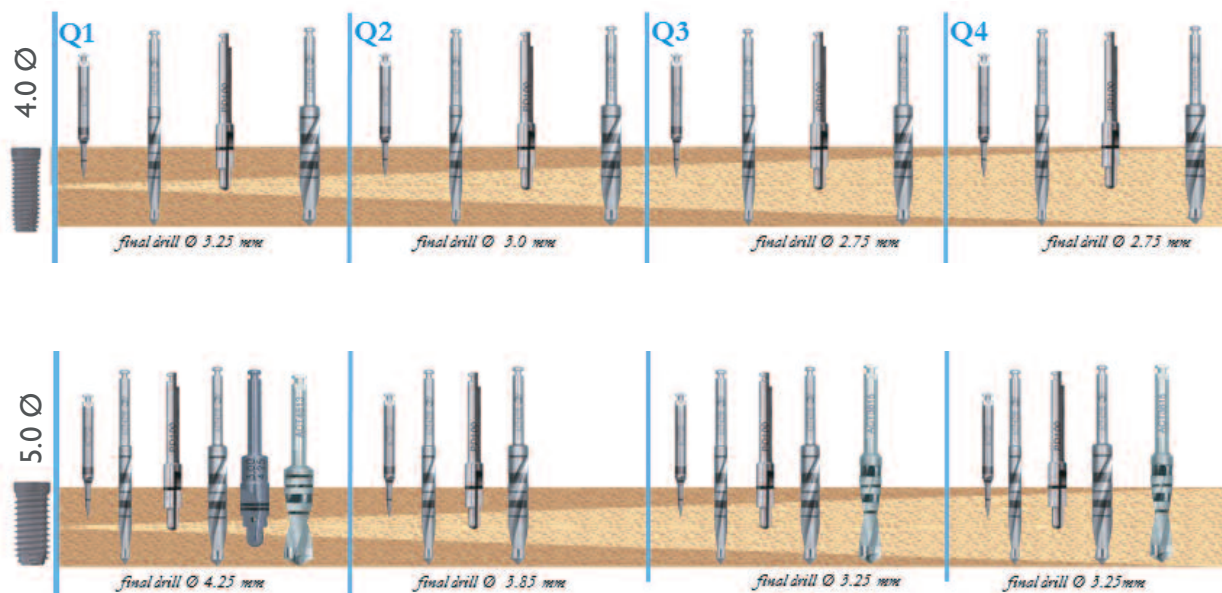


Fig. 4. Implants were placed according to a diagnostic drilling protocol, whereby selection of the final drill size was based on bone quality to increase initial stability. In Type I bone, the final drill size was 3.25mm (4.0mm implant diameter)/4.25mm (5.0mm implant diameter). In types II, III, and IV bone, the final diameter drill used to create the osteotomy was reduced in order to gain as much immediate bone-to-implant contact (IBIC) as possible.

The 30 partially edentulous and two edentulous cases included in the study (Table 2) were provisionally rehabilitated with the QuickBridge⁷ method. In Figure 5 a typical multi-unit treatment is illustrated.

Ten single-tooth implants were placed, and for these, a PreFormance[®] Post was adjusted for fabrication of a provisional restoration following a non-occlusal load protocol. All provisional restorations were made chairside. A prefabricated translucent crown shell (Frasaco, Germany) was filled with composite resin and pressed over the modified PreFormance Post/Temporary Cylinder. After light-curing the composite resin, the occlusal surface and interproximal contours of the crown were adjusted extraorally. The single-unit crowns were left out of occlusion and free from proximal contacts. Subsequently, the crowns were cemented with temporary cement. In Figure 6, a typical single-unit treatment is illustrated.

For the six cases (nine implants) that were performed with a one-stage approach, BellaTek[™] Encode[®] Healing Abutments (BIOMET 3i) were placed.

Three months after implant placement, a visit was scheduled to make a new impression for fabrication of a master cast onto

which the definitive fixed restoration would be fabricated. Some impressions were made using conventional implant impression copings and some used the BellaTek Encode Impression System, which enables a traditional or digital impression to be taken of the healing abutment. From the healing abutment impressions, CAD/CAM abutments were fabricated. For the partially edentulous/edentulous cases, BellaTek Copy Mill Frameworks with porcelain application were fabricated. For the single units, BellaTek Abutments and BellaTek Copings were made.

Follow-up Evaluation

All patients participating in the study agreed to follow a strict and individually designed maintenance program focusing on: (1) oral hygiene, (2) stability of the fixed restorations, (3) soft-tissue health, and (4) function of the dentition. Post-treatment follow-up examinations were scheduled for three, six, and 12 months.

Results

None of the 78 implants failed. The overall cumulative survival rate (CSR) for implants in the study was 100% after one year (Table 4).

Resonance Frequency Analyses, performed for all 78 study implants, yielded ISQ scores at implant placement ranging

OSSEOTITE® 2 Certain® Implants					
Bone Quality	Bone Quality				No. of Implants
	1	2	3	4	
A	0	2	0	2	4
B	0	13	18	4	35
C	1	13	12	5	31
D	5	0	1	2	8
Total	6	28	31	13	78

Table 1. Bone quality and quantity according to the criteria of Lekholm and Zarb.

from 59 to 85. The mean value was 76.0 (S.D 5.4). Final seating torque ranged from 30Ncm to 70Ncm. The mean value was 53.6. No significant difference could be seen between dense and soft bone regarding the ISQ value.

Scanning electron microscopy at 2000x magnification, conducted on representative implants, qualitatively demonstrated the presence of the characteristic 1- to 3-micron peak-to-peak irregularities of the OSSEOTITE® Surface.

Discussion

Treatment with dental implant-supported restorations has changed over the last few decades from a classic two-stage approach requiring long healing times to faster treatment models that include one-stage surgery, extraction and immediate placement, and immediate loading. Such new treatment concepts increase the demands upon clinicians, both from a surgical and prosthetic perspective.

To meet these demands, the author believes that surgical protocols should be customized. By measuring insertion torque and using RFA, the experienced surgeon can choose a combination of final drills and implants suited to the bone quality at each implant site. This can lead to better primary stability and improved clinical results. Other factors that can influence the clinical outcome are implant design and microgeometry, e.g. surface enhancements.

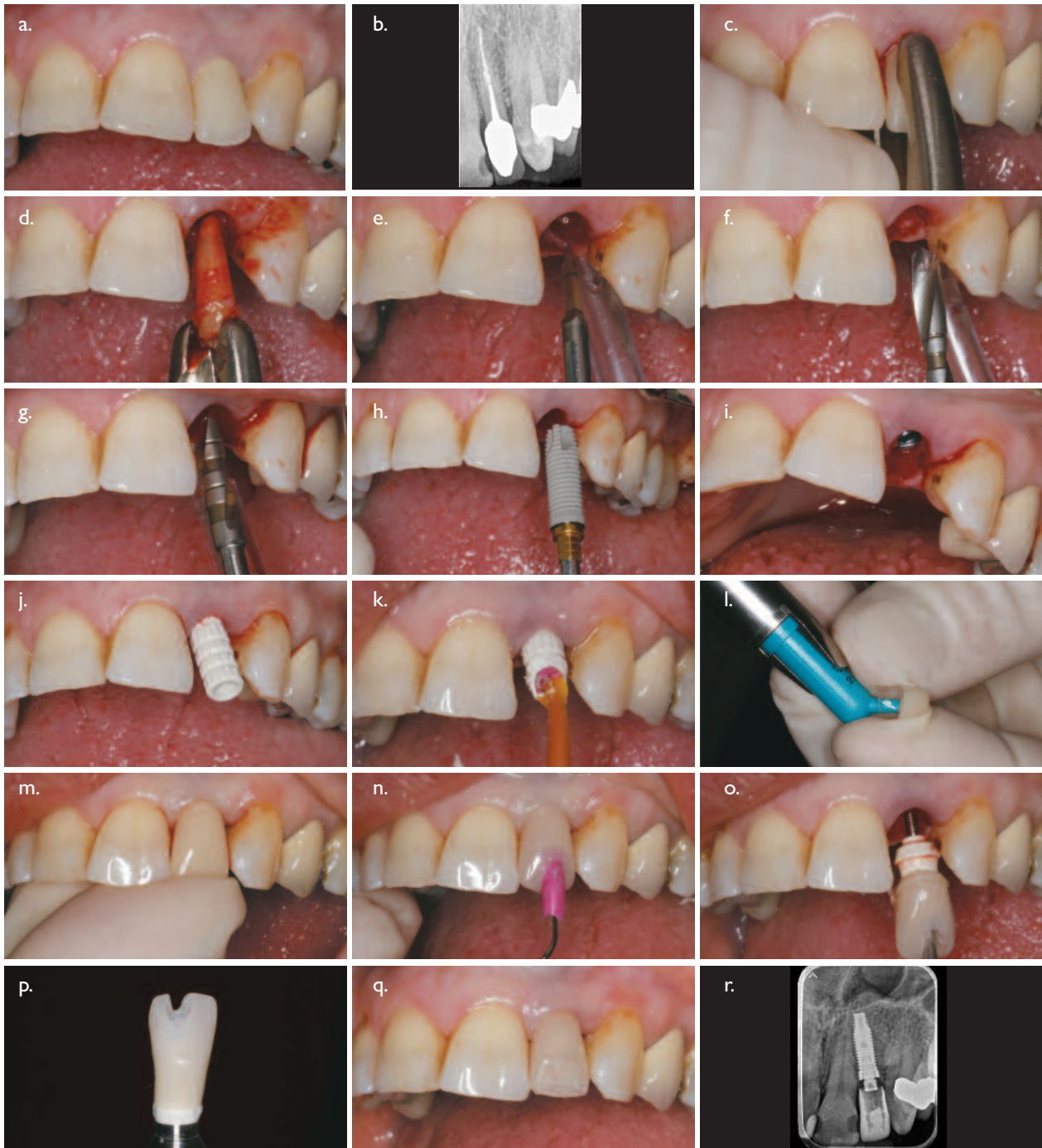The macrogeometric design of the implants used in the present study (including a reduced apical taper; modified cutting flutes; and a narrower thread pattern) may contribute to primary stability. In a previous study conducted by the author and co-workers,⁶ RFA was used to assess implants placed according to a surgical protocol that

Site	No. Prosthetic Constructions
Total Mandible	1
Total Maxilla	1
Partial Maxilla	20
Partial Mandible	10
Single Maxilla	4
Single Mandible	3
Total	39

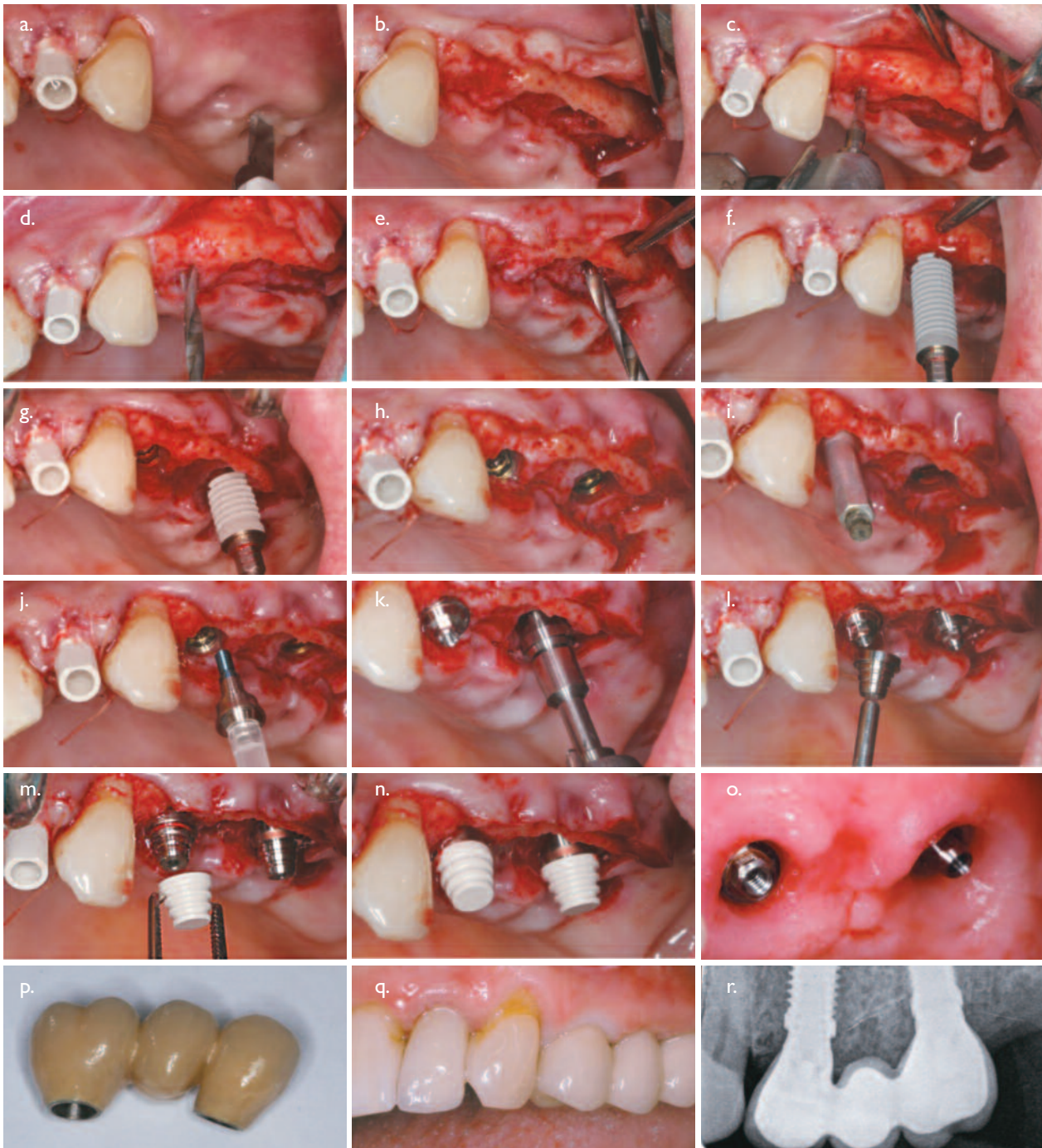
Table 2. Number of prosthetic constructions.

aimed for high primary stability. The aim was also to correlate the RFA measurements with factors related to the surgical technique, the patient, and the implant design. The results of measuring 905 Brånemark dental implants used in 267 consecutive patients showed a mean ISQ value of 67.4 (SD 8.6). A correlation between bone quality and primary stability was found, with lower ISQ values obtained for implants placed in softer bone. Lower stability values also correlated with decreased implant length. In the present study, the ISQ values after surgery were as high as 76.0 (S.D 5.4). The mean final insertion torque of 53.6Ncm also indicates high primary stability. One explanation for the high ISQ values may be the macrogeometry of the implant. The adaptive surgical protocol may also have contributed to the high ISQ values.

The OSSEOTITE 2 Certain Implant is manufactured from commercially pure titanium with the 1- to 3-micron peak-to-peak, dual-acid-etched (DAE) OSSEOTITE Surface. The large scale topography on which the features of the



Figs. 4a-c. A 59-year-old female patient presented with a root fracture of the maxillary lateral incisor; which required extraction. **Figs. 4d-f.** The fractured tooth root was removed, and the extraction site was prepared for implant placement. **Figs. 4g-i.** A 3.85mm diameter twist drill was used for final preparation of the osteotomy, and a 5.0mm x 13.0mm OSSEOTITE® 2 Certain® Implant was placed. **Figs. 4j-l.** A PreFormance® Temporary Cylinder was placed into the internal interface of the implant and trimmed for fabrication of a provisional Low Profile Abutment restoration. **Figs. 4m-o.** A crown shell fabricated from a clear template was filled with acrylic resin and seated over the PreFormance Post, then removed for modifications. **Figs. 4p-r.** The provisional restoration was completed extraorally, seated, and a periapical radiograph was taken. The patient left with a provisional restoration in place.



Figs. 5a-c. A 57-year-old female patient presented with several recently extracted and missing teeth in the maxilla. She desired fixed restorations. A midcrestal incision was made to reflect a flap. **Figs. 5d-f.** Preparation of the osteotomies was accomplished with a series of twist drills following the manufacturer's protocol. **Figs. 5g-i.** 4.0mm diameter OSSEOTITE® 2 Certain® Implants were placed into the prepared sites. An OSSTELL ISQ was placed to measure the ISQ value of the implants to determine primary stability. **Figs. 5j-l.** Either PreFormance® Temporary Cylinders or Low Profile Abutments were placed into the implants. The Low Profile Abutments were tightened to 20Ncm using a Standard Abutment Driver Tip and a torque device. **Figs. 5m-o.** QuickBridge® Titanium Temporary Cylinders were placed onto the abutments, followed by PEEK QuickBridge Caps for fabrication of a provisional restoration. **Figs. 5p-r.** Eight weeks later, the definitive restoration was placed, and a periapical radiograph was taken.

Implant Length	Diameter 4.0	Diameter 5.0	Total No.
15.0mm	24	20	44
13.0mm	12	4	16
11.5mm	1	2	3
10.0mm	7	6	13
8.5mm	2	0	2
Total	46	32	78

Table 3. Lengths of included implants.

Interval	Implants in Interval	Failures	CSR
0 – 6 months	0	0	100%
6 – 9 months	14	0	100%
9 – 12 months	47	0	100%
12 +	17	0	-

Table 4. Life-table of OSSEOTITE® 2 Certain® Parallel Walled Implants.

OSSEOTITE Surface are superimposed has an average surface roughness of Sa~.5 microns. It should be noted that in terms of surface roughness measured in this manner, the surface is still defined as minimally rough.⁸

The OSSEOTITE Surface is well documented. Histologic analysis⁹ indicated that at six months of unloaded healing, the mean BIC value for OSSEOTITE-Surfaced Implants (72.96% ± 25.13%) was statistically significantly higher (P < 0.05) than the mean BIC value for machined-surfaced implants (33.98% ± 31.04%). Trisi, et al¹⁰ studied the actual bone-to-implant contact for OSSEOTITE Implants. They found that the OSSEOTITE Surface showed a greater bone-to-implant contact than expected, whereas the actual bone-to-implant contact for machined-surfaced implants was mostly lower than the expected values. They concluded that the OSSEOTITE Surface appears to exert a positive effect on the amount of bone approaching the implant surface and can be described as conductive, while the machined surface is nonconductive.

Drago and Lazzara¹¹ reported on 93 OSSEOTITE Implants that were restored with fixed provisional crowns out of occlusion immediately after implant placement. Thirty-eight partially edentulous patients were included in the study. All implants were immediately restored with prefabricated

abutments and cement-retained provisional crowns without centric or eccentric occlusal contacts. The implants were restored with definitive restorations approximately 8 to 12 weeks after placement. All patients included in the study were followed for at least 18 months after implant placement. Seventy-seven of the 93 implants satisfied the inclusion criteria. Seventy-five implants became osseointegrated. The overall survival rate was 97.4%.

OSSEOTITE 2 Implants have an etched surface all the way to the top of the implant. An altered microtexture in the coronal part of an implant might have a bone-preserving effect. On the other hand, a rough surface exposed to the oral cavity might lead to peri-implantitis. Zetterqvist, et al¹² followed 112 patients who were enrolled at seven centers. They followed 139 control and 165 test implants (total: 304 implants). With more than five years of post-loading evaluations, there was one declaration of peri-implantitis associated with a control implant that was successfully treated later. Clinical probing and radiographic assessments did not reveal differences between groups in mucosal health outcomes or other signs of peri-implantitis. The researchers concluded that the studied material did not show any increased risk of peri-implantitis for fully etched implants compared to hybrid implants.

Conclusion

With this one-year follow-up study, OSSEOTITE® 2 Certain® Implants appear to be a viable option for implant rehabilitation. The indications that point to primary stability were present in this study and can provide the clinician with the option to pursue one-stage or immediate-loading protocols. Analysis of radiographic data gathered for this ongoing study, along with longer follow-up time, are required to confirm these initial findings.

References

1. Friberg B, Jemt T, Lekholm U. Early failures in 4,641 consecutively placed Brånemark dental implants: A study from stage I surgery to the connection of completed prostheses. *Int J Oral Maxillofac Implants* 1991;6(2):142-146.
2. Berglundh T, Persson L, Klinge B. A systematic review of the incidence of biological and technical complications in implant dentistry reported in prospective longitudinal studies of at least 5 years. *J Clin Periodontol* 2002;29(suppl 3):197-212.
3. Esposito M, Hirsch JM, Lekholm U, et al. Biological factors contributing to failures of osseointegrated oral implants (I). Success criteria and epidemiology. *Eur J Oral Sci* 1998;106:527-551.
4. Sennerby L, Rasmusson L. Osseointegration surgery: Host determinants and outcome criteria. In: Zarb GA, Lekholm U, Albrektsson T, Tenenbaum H (eds). *Aging, Osteoporosis, and Dental Implants*. Chicago: Quintessence, 2002:55-66.
5. Lekholm U, Zarb GA. Patient selection. In: Brånemark P-I, Zarb GA, Albrektsson T (eds). *Tissue-Integrated Prostheses: Osseointegration in Clinical Dentistry*. Chicago: Quintessence, 1985:199-209.
6. Östman PO, Hellman M, Wendelhag I, et al. Resonance frequency analysis measurements of implants at placement surgery. *Int J Prosthodont* 2006;19(1):77-84.
7. Östman PO, Hellman M, Sennerby L, et al. Temporary implant-supported prosthesis for immediate loading according to a chair-side concept: Technical note and results from 37 consecutive cases. *Clin Implant Dent Relat Res* 2008;10(2):71-77.
8. Wennerberg A, Albrektsson T. On implant surfaces: A review of current knowledge and opinions. *Int J Oral Maxillofac Implants* 2010;25(1):63-74.
9. Lazzara RJ, Testori T, Trisi P et al. A human histologic analysis of Osseotite and machined surfaces using implants with 2 opposing surfaces. *Int J Periodont Restorative Dent* 1999;19(2):117-129.
10. Trisi P, Lazzara R, Rao W, et al. Bone-implant contact and bone quality: Evaluation of expected and actual bone contact on machined and Osseotite implant surfaces. *Int J Periodont Restorative Dent* 2002;22:535-545.
11. Drago CJ, Lazzara RJ. Immediate provisional restoration of Osseotite implants: A clinical report of 18-month results. *Int J Oral Maxillofac Implants* 2004;19(4):534-541.
12. Zetterqvist L, Feldman S, Rotter B, et al. A prospective, multicenter, randomized-controlled 5-year study of hybrid and fully etched implants for the incidence of peri-implantitis. *Clin Oral Implants Res* 2007;18(2):153-160.

Pär-Olov Östman, DDS, PhD



Dr. Östman received his dental degree from the University of Umeå, Sweden. He received his PhD degree in the department of Biomaterials, Institute for Surgical Sciences, Sahlgrenska Academy, Gothenberg University, Gothenberg, Sweden. He is head of the "Team Holmgatan" private practice clinic in Falun, Sweden and Assistant Professor in the Department of Biomaterials, Institute for Surgical Sciences, Sahlgrenska Academy, Gothenberg University, Gothenberg, Sweden.

The contributing clinician has a financial relationship with BIOMET 3i LLC resulting from speaking engagements, consulting engagements, and other retained services.

editorial

Can we successfully manage patients on bisphosphonate therapy?



Robert E. Marx, DDS
 Professor of Surgery & Chief
 Division of Oral and
 Maxillofacial Surgery
 University of Miami
 Miller School of Medicine

Post-menopausal women constitute a significant subset of the patient population seeking to replace removable partial or full dentures with implant-supported restorations. This population may also be taking one of several available drugs to prevent or treat osteoporosis. Oral bisphosphonate therapy inhibits osteoclastic activity, and thus patients who are taking such drugs may be at risk for developing bisphosphonate-induced osteonecrosis of the jaw (BIONJ) following exposure of the bone during tooth extractions or placement of dental implants. For that reason, some authorities have suggested that osteoporotic women receiving oral bisphosphonate therapy may not be good implant candidates.

However, today the risks associated with bisphosphonates can be managed, and dental implants can be placed with little or no risk of BIONJ. Among the three most commonly prescribed oral bisphosphonates – Actonel® (risedronate sodium), Boniva® (ibandronate sodium), and Fosamax® (alendronate) -- Fosamax is the only one of major concern. Fosamax is given at twice the dose of the other two drugs, and it has been associated with a greater incidence of BIONJ. Among patients tracked in our database, Fosamax usage has accounted for 97% of such cases.

Implant candidates who are taking either Actonel or Boniva thus can be treated essentially like any other patient receiving implant therapy. For those taking Fosamax, the length of time on the drug is a critical consideration. Those who have taken it for two years or less appear to have normal bone healing, compatible with osseointegration. Taking Fosamax for more than two years, however, does appear to significantly increase the risk of impaired alveolar bone healing. Fosamax affects mature osteoclasts as well as the osteoclastic precursors in the bone marrow. It usually takes two or more years of drug usage for the number of mature osteoclasts to be reduced enough to affect osseointegration significantly, and if the patient continues taking Fosamax, a slow or impaired recovery of bone-marrow precursors will continue to threaten osseointegration.

What should clinicians do when presented with patients who desire dental implant therapy but have been taking Fosamax for several years? A first option is to have the patient tested for the serum marker C-terminal telopeptide (CTX). A by-product of normal bone turnover, this peptide sequence is the portion cleaved by osteoclasts during bone resorption. Serum levels of it are thus proportional to osteoclastic activity at the time the blood sample was drawn. A CTX level of more than 150 picograms per milliliter is a good indication that the patient's alveolar bone will heal normally following implant surgery and that the implants will successfully osseointegrate.

If ordering the test is not feasible, an alternative is for the patient to discontinue taking Fosamax, at least temporarily. Obviously, this should only be done with the approval of the patient's physician. However, most physicians are comfortable agreeing to such "drug holidays." The effects of bisphosphonate therapy are long-lasting; the drugs' half life is 11 years. Reliable research has shown that patients who have taken bisphosphonates for three to five years can stop using these drugs for up to five years without causing any change in osteoporotic status. Indeed, the US Food and Drug Administration has recently recommended that bisphosphonate drug companies improve their product descriptions to suggest limiting the duration of use.

As in all aspects of implant dentistry, the underlying biology must be respected. For patients receiving bisphosphonate therapy, the underlying biological processes create a window of opportunity. Clinicians must be willing to communicate with their physician colleagues in order to organize drug holidays for osteoporotic patients. Those who do so can enable those patients to get the therapy they want while protecting them both from osteoporosis as well as from the risk of BIONJ.

sinus

The clinical and histologic efficacy of xenograft granules for maxillary sinus-floor augmentation

Myron Nevins, DDS;^{1†} Marcelo Camelo, DDS;² Nicola De Angelis;³ James Hanratty, DDS;⁴ Wahn Khang;⁵ Jong-Jim Kwon, DDS, PhD;⁶ Giulio Rasperini, DDS;⁷ Isabella Rocchietta, DDS;⁸ Peter Schupbach, PhD;⁹ David Kim, DDS, DMSc¹⁰

What Was Done?

Techniques for augmenting pneumatized maxillary sinuses have proven to be safe and effective for creating sufficient amounts of vital bone to enable implant placement. A number of biocompatible and non-viable osteoconductive bone substitutes have been introduced to minimize the use of autogenous bone grafts. Bovine xenografts, whose chemical and physical properties are similar to those of human bone, have been effective in the formation of vital bone in the pneumatized sinus and have achieved high implant-survival rates. Hydroxyapatite xenograft granules (Endobon®, BIOMET 3i) derived from cancellous bovine bone have been introduced to function as a non-resorbable osteoconductive scaffold. The two-step processing of these granules (using pyrolysis at a temperature above 900°C and sintering at a temperature above 1,200°C) allows complete deproteinization, as well as destruction of potential residual bacteria, viruses, and prions. The aim of this study was to investigate the potential of xenograft granules to form vital bone in the non-natural bone-forming areas of maxillary sinuses.

How Was It Done?

At six dental offices, 14 sinus augmentations were performed in 14 patients, all of whom were documented to have less than 5mm of remaining alveolar bone height in the posterior edentulous maxilla. Lateral window osteotomies were created, and the exposed sinus membranes were elevated. The sinus cavities were filled with 500- to 1,000-µm granules of Endobon Xenograft Granules and covered with resorbable collagen barrier membranes (OsseoGuard®, BIOMET 3i). Primary closure was achieved. After six months, CT scans were taken,

and sinus-core biopsies were obtained, processed, and analyzed using both light and scanning electron microscopes.

What Were the Results?

Surgical outcomes were uneventful, and sufficient radiopaque volume was present radiographically to enable placement of dental implants. Clinical reentry at six months revealed bone formation at the osteotomy sites. The histologic evaluations showed the xenograft granules to be integrated and surrounded by woven bone. The granules appeared to be in close contact with the particles. Around some particles, rims of osteoblasts were observed depositing osteoid matrix. No inflammatory cells were noted around the particles, nor were there any obvious signs of xenograft resorption. The woven bone appeared to be undergoing remodeling and maturation to become well-organized lamellar bone.

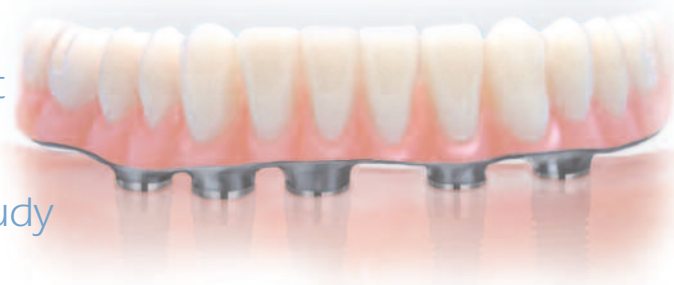Clinical Relevance

Predictable formation of vital bone can be achieved using osteoconductive Endobon Xenograft granules. No osteoclastic bone resorption was observed in the sinus-augmentation sites in this study. The two-step high-temperature processing undergone by the particles results in a crystalline-like structure of more than 95% of the hydroxyapatite, which probably explained the graft particles' slow resorption rate; HA resorption has been documented to increase as crystallinity decreases. It is possible that the amount of vital bone content could be additionally increased by lengthening the time until biopsy.

1. Associate Clinical Professor, Division of Periodontology, Department of Oral Medicine, Infection, and Immunity, Harvard School of Dental Medicine, Boston, Massachusetts, USA
2. Institute for Advanced Dental Studies, Belo Horizonte, Brazil
3. Assistant Professor, University of Genoa, Genoa, Italy
4. Private Practice, Swampscott, Massachusetts, USA
5. Clinical Assistant Professor, Department of Periodontics, University of Maryland Dental School, Baltimore, Maryland, USA
6. Professor, Department of Implant Center, Korea University Anam Hospital, Seoul, South Korea
7. Associate Professor, Department of Periodontology, School of Dentistry, University of Milan, Milan, Italy
8. Department of Periodontology, School of Dentistry, University of Milan, Italy
9. P.Schupbach Histology, Research Laboratory, Biomaterials, Horgen, Switzerland
10. Assistant Professor, Division of Periodontology, Department of Oral Medicine, Infection, and Immunity, Harvard School of Dental Medicine, Boston, Massachusetts, USA

[†]The contributing clinician has a financial relationship with BIOMET 3i LLC resulting from speaking engagements, consulting engagements, and other retained services.

Volumetric determination of the amount of misfit in CAD/CAM and cast implant frameworks: A multicenter laboratory study



Carl Drago, DDS, MS;^{1†} Roxana L. Saldarriaga, DDS;² Daniel Domagala, DDS, MS;³ Riad Almasri, DDS⁴

Why Was This Research Done?

Clinicians have struggled for decades to formulate a clear definition of an acceptable clinical fit between implants and frameworks. Jemt in 1991 found distortions between frameworks and osseointegrated dental implants of up to several hundred microns. When he and Book prospectively studied prosthesis misfit in 14 patients, they found the mean centerpoint misfit was 111 μm (SD 59) and 91 μm (SD 51) for the 1- and 5-year groups, respectively, with a range of 275 μm . The corresponding mean marginal bone loss was 0.5 and 0.2mm for the two follow-up groups. Although findings such as these have been replicated by numerous researchers around the world, agreement over clinical acceptability has never been reached.

What Was Done?

The authors sought to evaluate the accuracy of implant-supported frameworks made with two different processes: CAD/CAM (computer-aided design/computer-aided manufacturing) and traditional lost-wax casting. The CAD/CAM approach involved using tactile scanning; a sophisticated computer-software program recorded and measured the volumetric differences between CAD/CAM-fabricated and conventionally cast frameworks and implants. As framework misfits typically are three-dimensional, the authors felt that measuring and comparing the components volumetrically would yield new insights into the question of framework-to-implant fit.

How Was It Done?

Three residents from three different prosthodontic residency university programs agreed to use the same protocol. Plastic patient models were fabricated (one for each university) that simulated a mandibular edentulous patient with five interforaminal implants. Impressions, master casts, and verification indexes were made. One set of casts was scanned, and one set of casts was used to fabricate metal frameworks

conventionally. All the frameworks were made to similar specifications. Five BellaTek™ Bars (formerly known as CAM StructSURE® Precision Milled Bars) (BIOMET 3i) were made for one group of casts. Conventional one-piece castings with silver-palladium alloys were made for the second group of casts. The restorative platforms of the implants were scanned, as were the restorative platforms of each of the frameworks. A software engineer who performed "virtual one-screw tests" then manipulated the digitized data. The results were tabulated, and the volumetric spaces between the frameworks and implants were compared.

What Were the Results?

The CAD/CAM frameworks fit significantly better than the cast gold frameworks ($P < .0001$). On average, the volumetric misfit between the CAD/CAM framework platforms and the implants was 2.25mm³ less (better) than the corresponding volumetric misfit between the implant-restorative platforms of the castings and the implants.

Clinical Relevance

In this laboratory study, the CAD/CAM technologies featured resulted in implant-supported frameworks that were significantly more accurate than conventionally fabricated cast frameworks. The software used in this study was able to accurately interpret the digital data relative to the small volumetric differences between implants and implant-restorative platforms of the cast and CAD/CAM-fabricated frameworks. The linear differences were on the order of 10-20 microns--significantly better than the misfits described in the 1990s. However, this was a laboratory study, the question as to what are clinically acceptable fits remains unanswered. Also not answered by this research is the question of how important an accurate passive fit between implants and frameworks is and how much of a framework misfit can be biologically tolerated. These questions deserve further study.

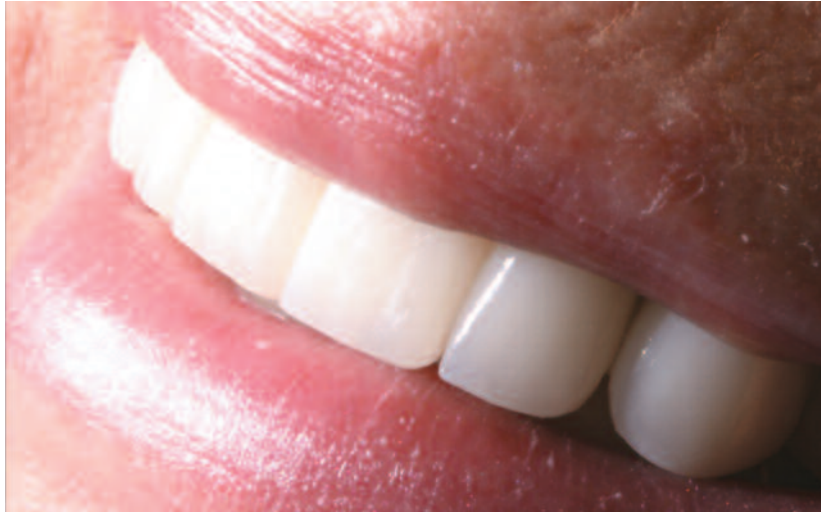1. Associate Professor, The Ohio State University College of Dentistry, Columbus, Ohio
2. Prosthodontic Resident, University of Minnesota School of Dentistry, Minneapolis, Minnesota.
3. Prosthodontic Resident, Marquette University School of Dentistry, Milwaukee, Wisconsin.
4. Resident in Postgraduate Prosthodontics, Nova Southeastern University, College of Dental Medicine, Fort Lauderdale, Florida.

[†]The contributing clinician has a financial relationship with BIOMET 3i LLC resulting from speaking engagements, consulting engagements, and other retained services.

CLINICAL CASE PRESENTATION

A staged approach to implant therapy for a patient transitioning from partial removable prostheses to fixed implant-supported restorations

Robert G. Ritter, DMD[†] & Karina Leal, DMD



Although restoration of the edentulous maxilla is always challenging, one potentially complicating factor is eliminated if a patient presents with removable prostheses and expresses a desire to replace them with a fixed restoration. This clinical presentation illustrates the use of a staged approach to the transition from partial removable (coping-sleeve) prostheses to delivery of fixed, porcelain-fused-to-metal implant-supported restorations.

Key Words: staged approach, implant-supported restorations, GingiHue® Abutments

Introduction

As has been discussed by Drago and Carpentieri in this journal, creation of a fixed prosthesis requires a sufficient volume of oral space. When the surgical and restorative space is determined to be adequate, attention may shift to the question of how best to temporize the patient between implant placement and delivery of the definitive restoration.

In the following clinical case, the decision was made to continue using the removable, tooth-supported prostheses throughout the initial implant-healing period. However, in the second phase of treatment, extraction of the remaining hopeless natural dentition was accompanied by delivery of a fixed acrylic provisional restoration, substantially accelerating the achievement of the patient's ultimate goal of improved retention. The choice to utilize off-the-shelf titanium abutments to support both the provisional and definitive restorations also simplified the treatment costs and resulted in good soft-tissue healing.

The Decision-Making Process

Patient Preference: Fixed restorations

Patient Finances: Excellent

Clinical Factors: Adequate surgical and restorative space for fixed prostheses

Patient Compliance: Excellent

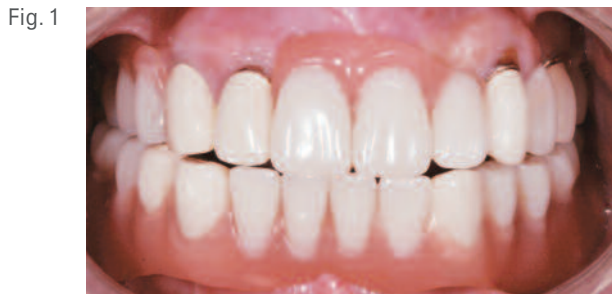

Fig. 1

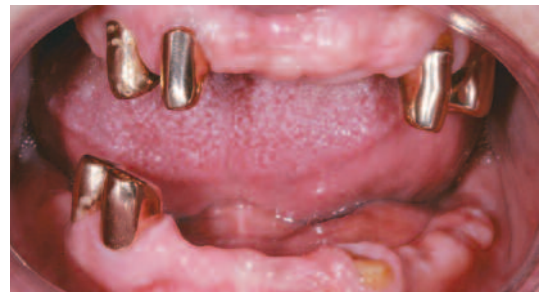

Fig. 2

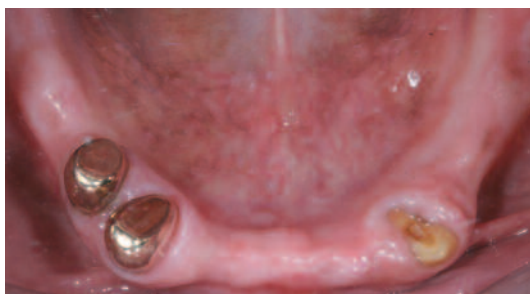

Fig. 3

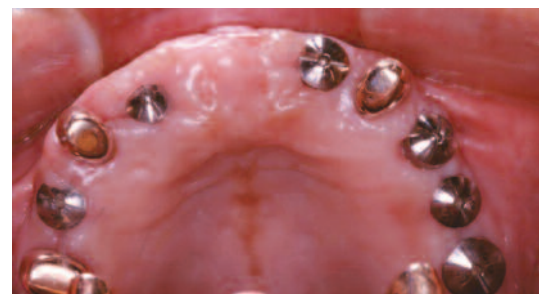

Fig. 4

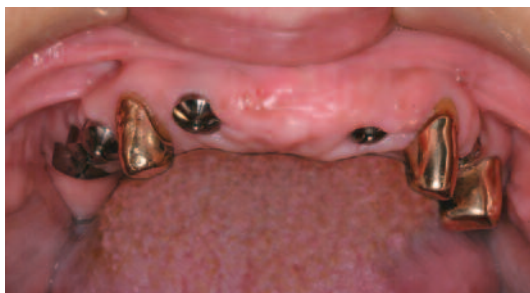

Fig. 5

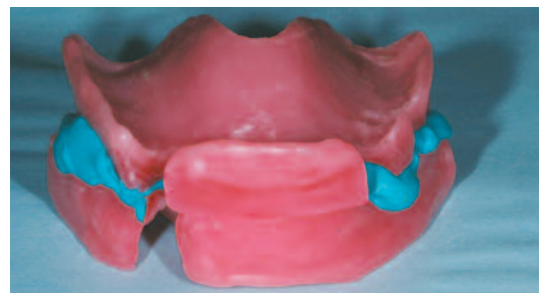


Fig. 6

Clinical Presentation

The 62-year-old patient presented with existing maxillary and mandibular removable partial dentures (coping-sleeve prostheses) (Fig. 1). They were supported by a few remaining natural teeth in each arch that were restored with gold alloy telescopic copings (Figs. 2 and 3). The patient's chief complaint was loss of retention of the dentures. Clinical and radiographic findings revealed that two (one maxillary and one mandibular) of the abutments were fractured, and two others exhibited decay and periodontitis.

The patient desired a fixed solution, if possible, to replace her failing dentition. Diagnostic data were gathered, including preliminary records and occlusal registration. The vertical dimension of occlusion (VDO) was also recorded with the removable prostheses in place.

The patient was offered the option of being treated with either screw-retained fixed hybrid prostheses or

cement-retained porcelain-fused-to-metal (PFM) fixed partial dentures. The benefits and potential limitations of the two treatment approaches were discussed thoroughly. They are as follows:

Screw-Retained Fixed Hybrid Prostheses Benefits:

An acrylic resin restoration typically costs less and may provide more optimal lip support. The ability to retrieve the restoration provides for easier maintenance.

Limitations:

Bulkier gingival contours may make routine hygiene more challenging. The softer acrylic material is also less abrasion-resistant and more susceptible to wear.

Cement-Retained PFM Fixed Partial Dentures Benefits:

A PFM restoration is stronger and potentially more aesthetic. The potential for developing anatomic emergence profiles is high. Less bulky, it is easier to clean.

Fig. 7

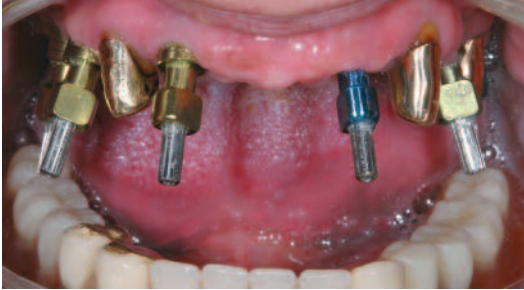

Fig. 8

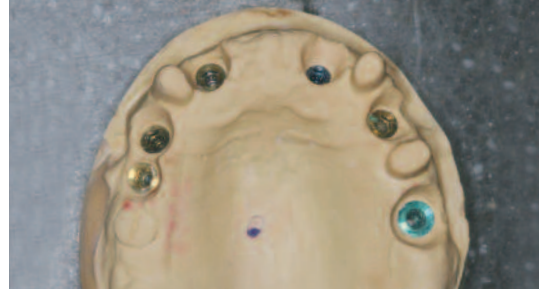

Fig. 9

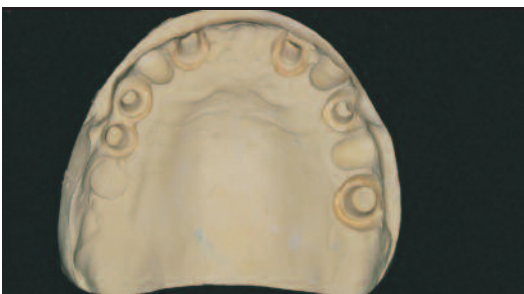

Fig. 10

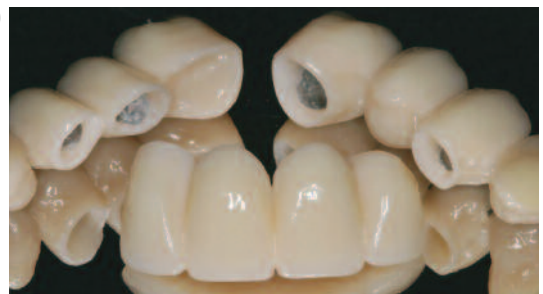

Fig. 11

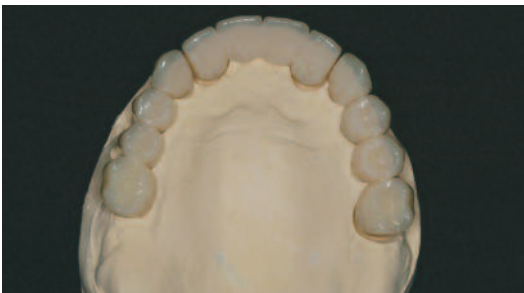
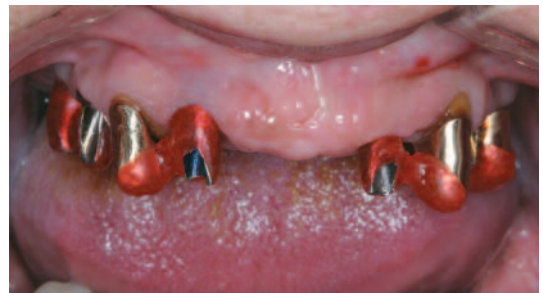
Fig. 12



Limitations: Initial costs are higher and professional maintenance costs may be higher because of the reduced retrievability. Adequate lip support may also be more difficult to achieve.

The patient chose fixed cement-retained prostheses, to be delivered in a staged approach. This included two-stage implant placement and unloaded healing, during which she would continue to wear her existing removable partial dentures. Fixed, implant-retained provisional restorations would then be placed, followed by delivery of the definitive restorations.

Surgical Treatment

On the day of surgery, six implants were placed in the maxilla and six in the mandible. The implants were submerged and allowed to heal unloaded. At the time of the second-stage surgery, three months after implant placement, 12 EP® Healing Abutments (BIOMET 3i) were placed, and the patient was dismissed wearing the existing removable overdentures.

Restorative Treatment

Eight weeks later, the patient was seen in the restorative office for evaluation (Figs. 4 and 5). Wax occlusion rims were fabricated to record the existing vertical dimension of occlusion (VDO) (Fig. 6).

The healing abutments were removed, pick-up implant impression copings were placed (Fig. 7), and radiographs were taken to confirm accurate and complete seating. Custom trays were then used to make open-tray heavy body polyvinylsiloxane (Imprint™ 3 Penta™ Putty, 3M™ ESPE™, St. Paul, Minnesota, USA) impressions of the implant positions. Shades were selected for the definitive restoration, the Healing Abutments were reconnected, and the patient was dismissed, once again wearing the removable partial dentures.

In the laboratory, implant analogs were mated with the impression copings within the impression. Master casts were

Fig. 13

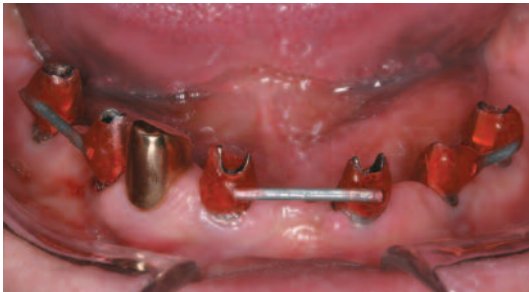

Fig. 14

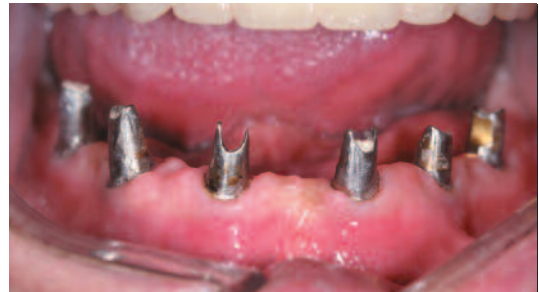

Fig. 15

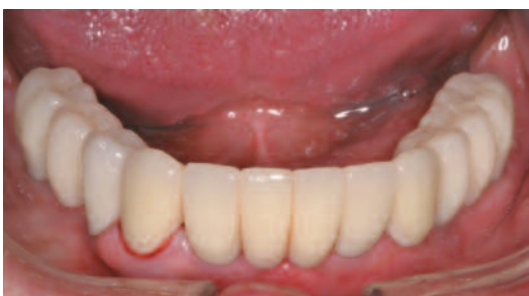

Fig. 16

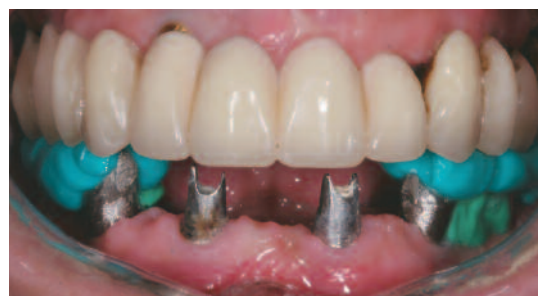

Fig. 17

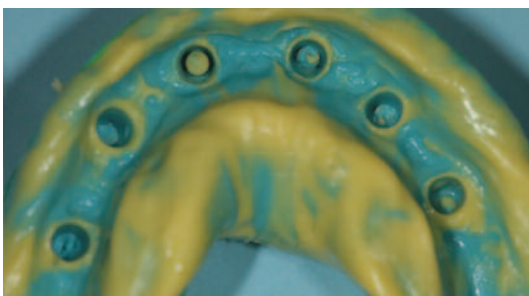
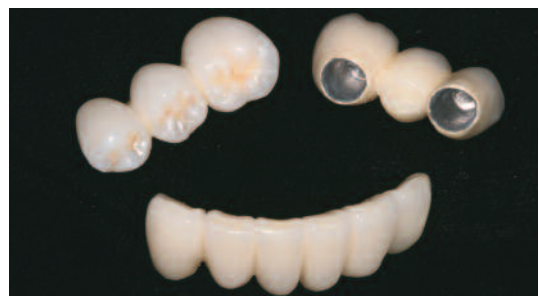

Fig. 18



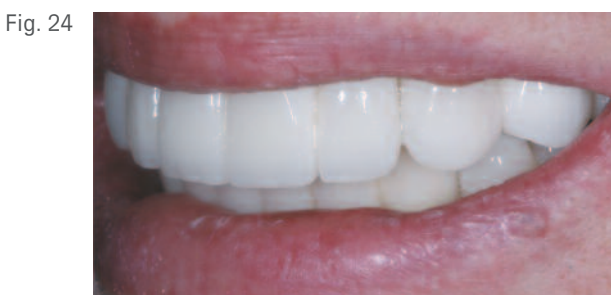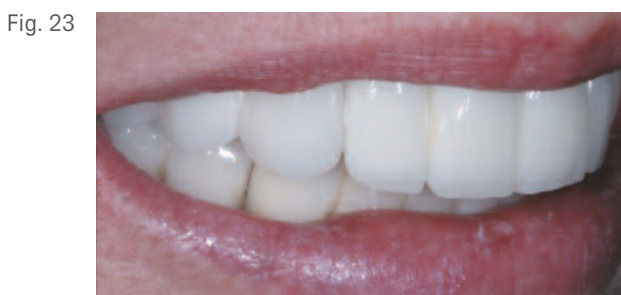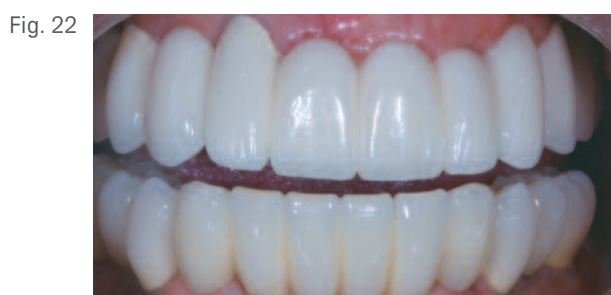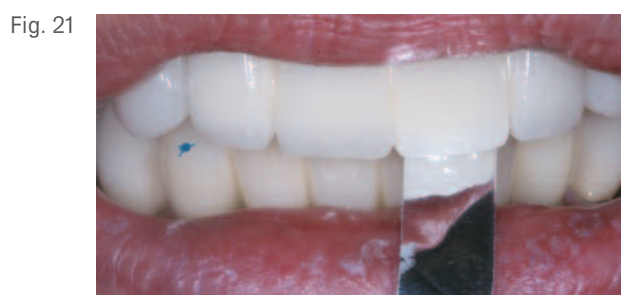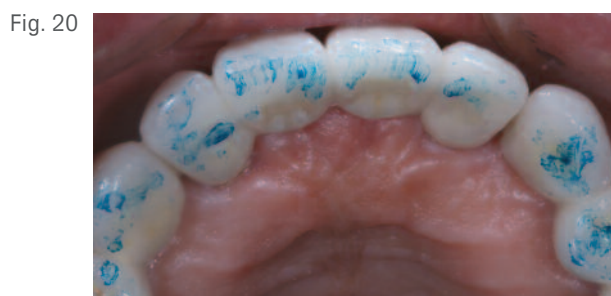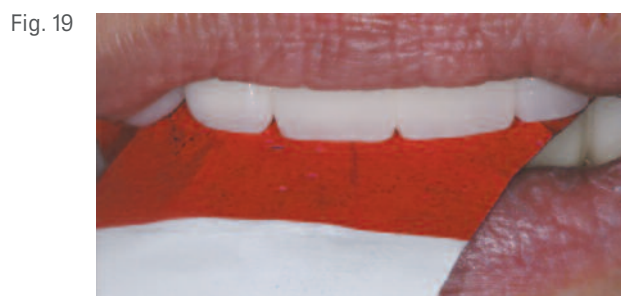poured in die stone (Fig. 8) and then articulated using the occlusion rims at the predetermined VDO. Appropriately-sized GingiHue® Posts (BIOMET 3i) were sent along with the casts to the laboratory for preparation. Definitive impressions were made of the prepared abutments (Fig. 9), poured in die stone, and mounted according to the occlusion at the same VDO as the original mounting. These master casts were sent to BioTemps Dental Laboratory (Irvine, California, USA) for fabrication of acrylic-resin provisional restorations. Cast metal frameworks were incorporated into the provisional restorations for strength. They were made in three segments for ease of placement and retrievability (Fig. 10).

The GingiHue Posts prepared in the laboratory and the provisional restorations were returned to the clinician for placement intraorally (Fig. 11). Placement of the prepared abutments was facilitated by the use of custom-fabricated indexes (PATTERN RESIN™ LS, Self-Curing Acrylic Die Material, GC America, Alsip, Illinois, USA) (Figs. 12 and 13). Periapical radiographs were taken to confirm complete

seating into the internal interfaces of the implants, and the abutments were secured with Gold-Tite® Abutment Screws (BIOMET 3i) that were hand-tightened (Fig. 14).

In the restorative office, the patient was anesthetized and the four remaining teeth were extracted. The provisional restorations were tried in. The occlusion was adjusted with even contacts throughout in centric occlusion; right and left working occlusion was group function. There were no balancing side contacts. Cotton pledgets were placed into the screw-access openings of the abutments, and the provisional restorations were secured with temporary cement (Fig. 15).

Post-operative healing was uneventful, and four months later, the restorative dentist made alginate impressions of the provisional restorations, to be used as a guide for fabricating the definitive restorations. To preserve the vertical dimension, the provisional restorations were removed segmentally and sequentially. Occlusal registrations were recorded; the two posterior segments were performed at one time (Fig. 16),



followed by the anterior segment. Two of the maxillary GingiHue® Posts required minor modification of the cervical margins to compensate for soft-tissue remodeling after healing. A new impression was made of the maxillary GingiHue Posts and sent to the dental laboratory (Fig. 17).

Soft-tissue models were fabricated with concurrent light-body impression material to reproduce the soft-tissue architecture. The impressions of the GingiHue Posts were made to verify that the abutments had not changed position and to confirm the soft-tissue contours.

In the laboratory, a soft-tissue replica was created on the original master cast to reflect the existing soft-tissue architecture. The laboratory then fabricated three FPDs per arch. Porcelain was applied to the frameworks in conventional fashion (Fig. 18). The patient returned for insertion of the definitive restorations in the mandibular arch. Due to the patient's travel schedule, placement of the definitive restorations in the maxillary arch was delayed until one month later.

At each of the definitive restorative appointments, the provisional restorations were removed. The definitive restoration segments were tried in intraorally, verified for fit, and complete seating was confirmed radiographically. The restorations were secured with Gold-Tite® Abutment Screws. The screws were tightened to 20Ncm of torque with a Low Torque Indicating Ratchet Wrench (L-TIRW) (BIOMET 3i). The screw-access openings were restored with light-body impression material (Imprint 3) and allowed to set. Definitive cementation was accomplished with Temrex® Cement (Temrex Corporation, Freeport, New York, USA).

Definitive occlusal equilibration was accomplished using Horseshoe 200 Micron X-Thin Articulating Paper (Fig. 19) (Bausch Articulating Papers, Inc., Nashua, New Hampshire, USA) to eliminate occlusal contacts (Fig. 20) within the Posselt's Envelop of Motion.¹ With the patient in centric occlusion, 8-micron shim stock strips were pulled through the anterior restorations to confirm clearance of the occlusion (Fig. 21). The patient was given oral hygiene

Robert G. Ritter, DMD & Karina Leal, DMD (continued)

instructions and released with the definitive restorations in place (Fig. 22). The patient was very pleased with the aesthetics of her smile (Figs. 23 and 24).

Clinical Relevance

This clinical presentation demonstrates a staged approach to treating a patient with failing dentition that had been supporting removable partial dentures in both arches. The use of a fixed provisional restoration after implant placement and healing enabled the restorative clinician to more quickly satisfy the patient's strong desire to replace her removable prostheses with fixed ones. At no time did she have to function without teeth. The choice to use stock straight titanium abutments and traditional crown and bridge protocols also offered advantages. In addition to being less expensive, the abutments, once placed, never had to be removed, helping to preserve the bone levels around the implants following development of the biological width.

Reference:

- 1. Posselt U. Physiology of Occlusion and Rehabilitation by Ulf Posselt. Second edition. Philadelphia: F.A. Davis Company, 1968.


Laboratory Colleague: Dave Haley, Prolab Dental Arts, Naples, Florida.

Robert G. Ritter, DMD



Dr. Ritter received his dental degree from the Medical University of South Carolina, College of Dental Medicine, Charleston, South Carolina. He is a member of the American Dental Association and the American Academy of Cosmetic Dentistry. He serves on the board of the Florida Academy of Cosmetic Dentistry, the American Equilibration Society, and the International Association of Dental Research. Dr. Ritter has published many articles on adhesive and cosmetic dentistry and is on the editorial board of Spectrum Magazine, the Journal of the American Academy of Cosmetic Dentistry, and Reality Magazine. He lectures nationally and internationally on cosmetic dentistry, new materials, and joint-based dentistry. He maintains a private practice with a focus on adhesive aesthetic dentistry in Jupiter, Florida.

Karina Leal, DMD



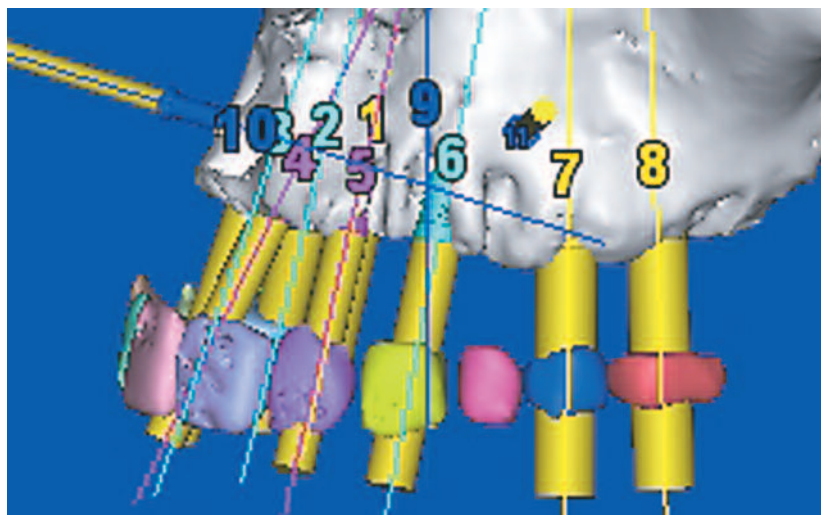
Dr. Leal received her dental degree and Certificate in Periodontics from Temple University School of Dentistry. She is a Diplomate of the American Board of Periodontology and a member of numerous organizations including the Pierre Fauchard Academy. Dr. Leal has co-authored and been credited in numerous articles on periodontal aesthetics and implant dentistry. She maintains a private practice limited to periodontics and implant treatment in West Palm Beach and Jupiter, Florida.

†The contributing clinician has a financial relationship with BIOMET 3i LLC resulting from speaking engagements, consulting engagements, and other retained services.

CLINICAL CASE PRESENTATION

Treatment of atrophic maxillae with computed tomography (CT) guided implant surgery

Robert A. del Castillo, DMD[†] & Thomas Peterson, CDT, MDT



CT technology and associated software have greatly enhanced the ability of clinicians to plan and carry out treatment with dental implants. Implants can be placed virtually to optimize the restorative results, and an accurate surgical guide can be fabricated. Flapless surgery can be carried out using precise instrumentation, and when adequate bone is present, patients can receive aesthetic fixed provisional restorations on the day of implant surgery. This article presents a case for which CT scanning, sophisticated planning software, and CAD/CAM technology were used to guide treatment for a patient with failing maxillary dentition due to advanced periodontitis.

Key Words: Tapered Navigator® System, CT guided, immediate provisionalization, Low Profile Abutments

Introduction

Carpentieri and Drago have identified key differences between maxillary and mandibular jaws including different resorptive patterns, anatomical factors, and loading patterns. They also identified three factors that need to be considered when comparing maxillary and mandibular treatments, including aesthetics, phonetics, and prosthesis design and fabrication. Complex treatments that involve periodontally compromised dentition and/or malocclusions begin with thorough clinical examinations, diagnostic casts, wax patterns or dentures, and radiographs prior to developing a diagnosis and treatment options. Patient expectations have become quite high, and for the most part, patients wish to proceed with prosthetic treatments that include implant placement immediately after extraction and insertion of immediate, functional, fixed interim prostheses.

The Decision-Making Process

Patient Preference: Fixed restorations

Patient Finances: Moderate

Clinical Factors: Adequate surgical and restorative space for fixed prostheses

Patient Compliance: Excellent

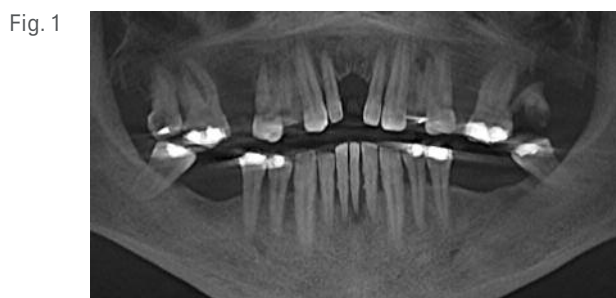


Fig. 1

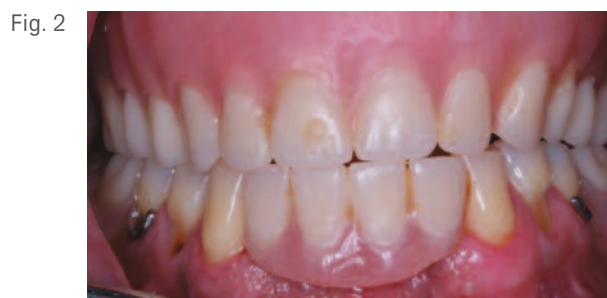

Fig. 2

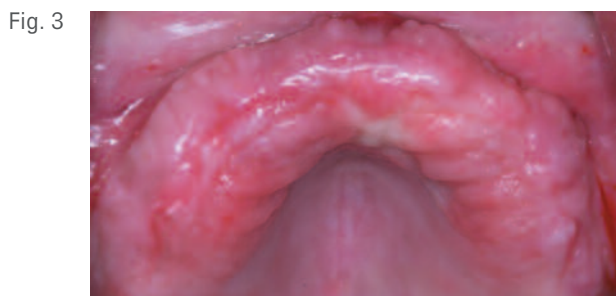

Fig. 3

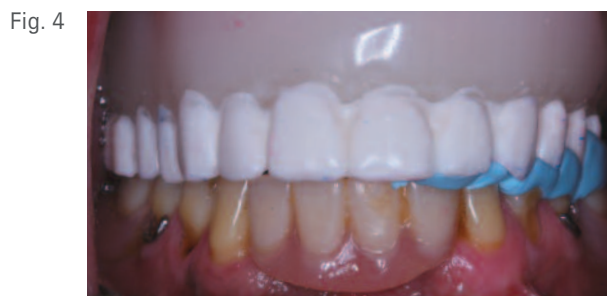

Fig. 4

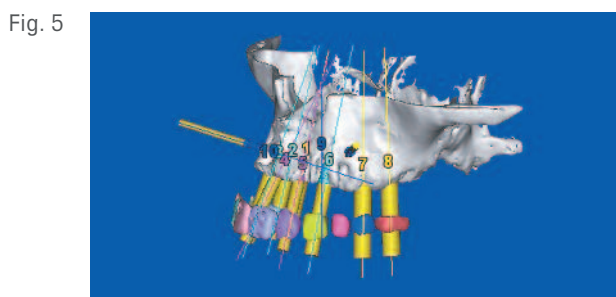


Fig. 5

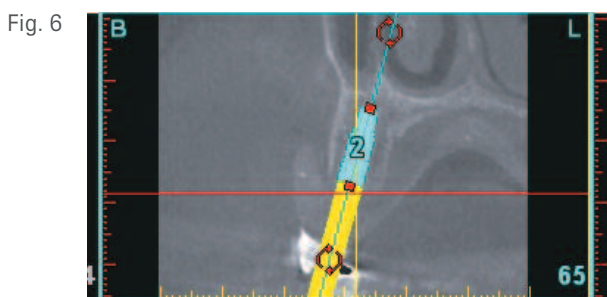


Fig. 6

In the following case, the decision was made to use CT three-dimensional imaging for both diagnostic and therapeutic purposes in treating a patient with an ill-fitting, unsatisfactory maxillary complete denture. The immediate implant-retained fixed provisional restoration included a cast-metal framework for increased strength. The provisional restoration was fabricated from the digitized data of the CT scan. The periodontist completed the restoration with intraoral procedures that involved attaching the provisional restoration to the restorative components placed immediately after implant placement.

Clinical Presentation

A 51-year-old male patient presented to the periodontist complaining that all his maxillary teeth and his mandibular front teeth were loose. His medical history was significant for long-term smoking. The patient's initial radiograph consisted of a Cone Beam CT (CBCT) scan. The radiograph revealed generalized, advanced periodontitis (Fig. 1). All maxillary teeth as well as the mandibular incisors were deemed hopeless.

The patient elected to have the maxillary teeth and the mandibular incisors extracted and replaced with immediate removable prostheses (Fig. 2). Healing was uneventful. However, the patient could not tolerate the maxillary complete denture and decided to have maxillary implants placed (Fig. 3). Although unable to function with the maxillary denture, he was generally pleased with the aesthetic results, which was duplicated for use as a scanning appliance (Fig. 4). An intraoral interocclusal record was made to compensate for the lack of a stable centric occlusal position for the scanning appliance. This is critical to ensure correct positioning of the scanning appliance during the scan.

A second CBCT scan was taken with the scanning appliance in place (Fig. 5). The surgeon was able to place implants virtually in relation to the radiographic tooth positions; none needed to be placed into embrasures. For example, in CBCT slice #65 (Fig. 6), the location of the implant is completely within the confines of the alveolar ridge, below the floor of the maxillary sinus, and centered within the radiopaque

Fig. 7

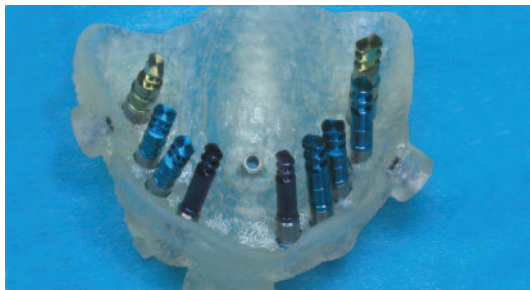

Fig. 8



Fig. 9



Fig. 10

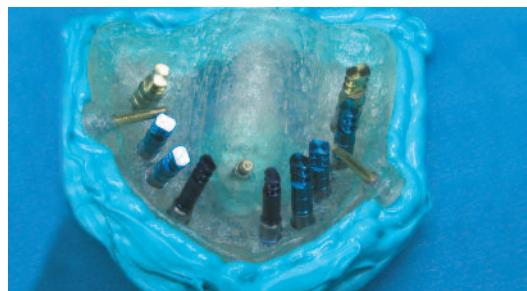

Fig. 11

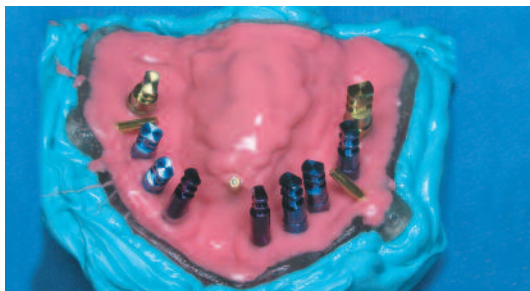
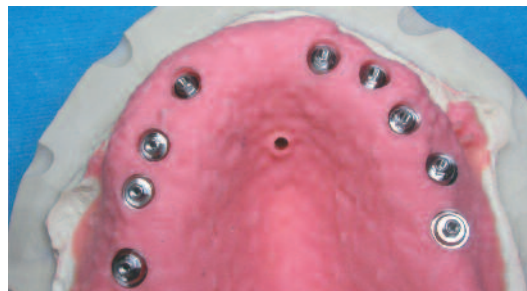

Fig. 12



artificial tooth. This represented an ideal position for the 4mm diameter implant. Angle correction was not needed. Therefore, the screw-access opening could be located within the occlusal surface of the provisional restoration. Because the bone thickness and height and the jaw relationship (Class I) were acceptable, a screw-retained restoration was designed to be used as the provisional prosthesis. The digital data relating to the planned implant positions were sent to Materialise Dental Inc. (Leuven, Belgium) for creation of the Surgical Plan and Surgical Guide.

Laboratory Procedures

The stereolithographic Surgical Guide was fabricated using a CAD/CAM process at Materialise Dental and sent to the commercial dental laboratory for use in creating the master cast. Laboratory analogs consistent with the sizes of the planned implants were mated to Navigator® Analog Mounts from the Tapered Navigator Laboratory Kit (Figs. 7 and 8). The notches in the guide tubes were aligned with the pins in the Analog Mounts (Fig. 9). This ensured proper hex

orientation, which was critical for transfer of the laboratory orientation of the implant analog hexes to the exact implant locations intraorally.

Polyvinylsiloxane impression material was used to box the Surgical Guide (impression) (Fig. 10). Soft-tissue replication material was injected around the implant analogs and covered the entire intaglio surface of the Surgical Guide (Fig. 11). Dental stone was poured into the Surgical Guide, and the master cast was fabricated. Low Profile Abutments were placed into the positions on the master cast dictated by the treatment plan (Fig. 12). Since the implants were placed axially and confined within the tooth portions of the restoration, angle corrections were not needed. A combination of implant restorative components was planned to be used within the provisional restoration.

The scanning appliance was placed onto the maxillary master cast (Fig. 13), and the casts were mounted in the articulator. The scanning appliance was removed from the master cast

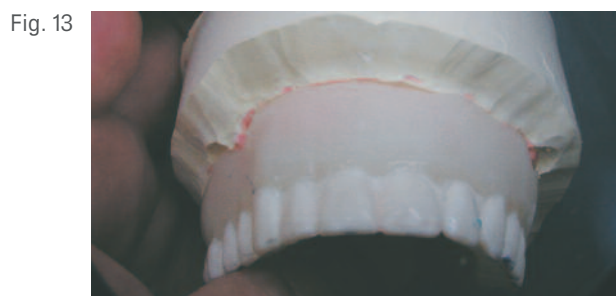

Fig. 13



Fig. 14

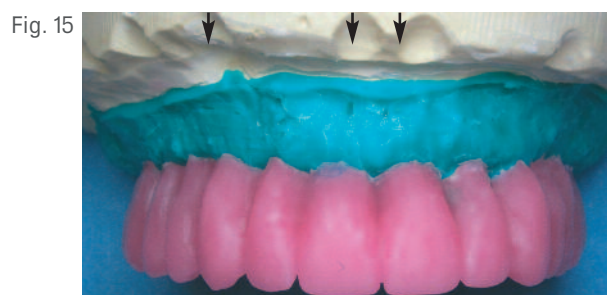


Fig. 15



Fig. 16

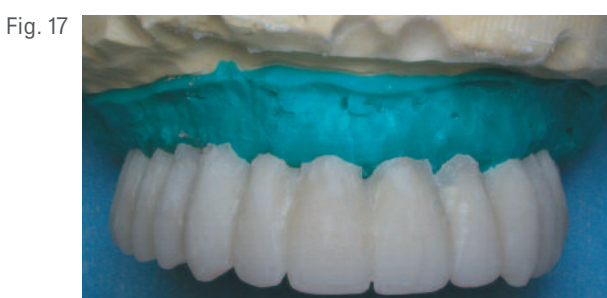

Fig. 17

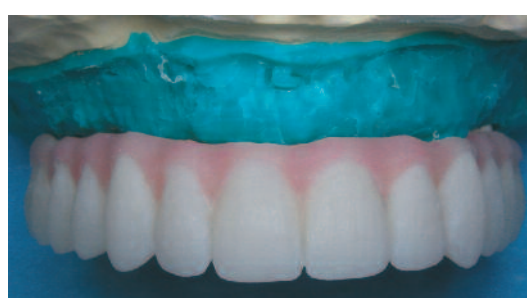

Fig. 18

and replaced with the Surgical Guide. The Surgical Guide was positioned at the same vertical dimension of occlusion as the pre-existing maxillary complete denture. A laboratory record was made of this relationship to facilitate optimal placement of the Surgical Guide intraorally during the implant-placement surgery (Fig. 14).

A laboratory silicone putty was used to fabricate a facial index of the teeth in the scanning appliance. The land areas of the master cast had previously been notched. The scanning appliance was removed from the master cast, and non-hexed Low Profile Abutment Temporary Cylinders were placed onto the abutments in the master cast. The implant sites in the maxillary lateral incisor areas were to be restored with non-hexed implant temporary cylinders. Full-contour wax patterns were fabricated for optimal form and occlusion (Fig. 15). Laboratory polyvinylsiloxane putty was used to make a facial index of the wax patterns. The notches in the land areas of the cast were used to reorient the facial index to its correct position.

A new wax pattern was developed for casting a metal framework and made consistent with the tooth positions within the facial index. The framework was made in this fashion to give the provisional restoration more strength. The design provided enough clearance between the framework and the temporary cylinders to enable the use of acrylic resin to connect the provisional restoration to the restorative components.

The framework was cast and finished in a base metal alloy (Fig. 16). With this particular laboratory protocol, no part of the framework contacted any portion of any of the restorative components. All but one of the components were to be attached to the interim restoration via an intraoral pick up technique. The temporary cylinder corresponding to the maxillary right lateral incisor was processed into the restoration.

Full-contour wax patterns were waxed directly on the framework (Fig. 17). In addition to losing bone as a result of his advanced periodontitis, this patient had also lost a significant

Fig. 19

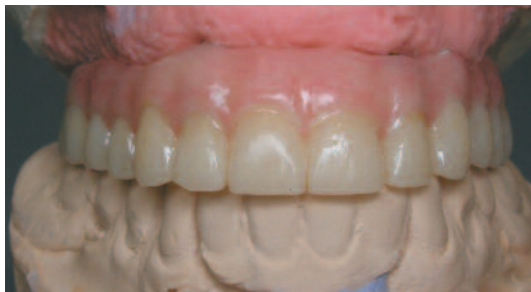

Fig. 20

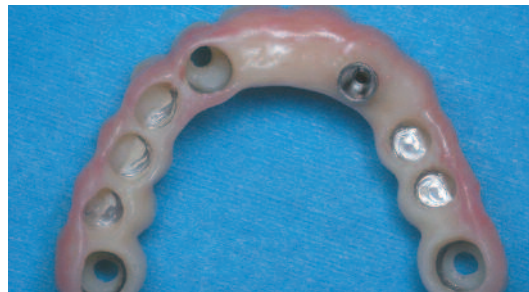

Fig. 21

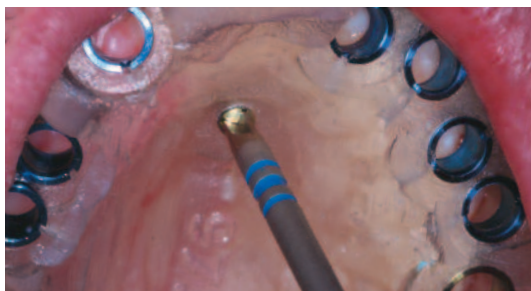

Fig. 22

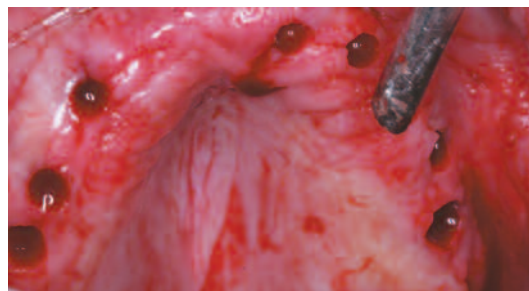


Fig. 23

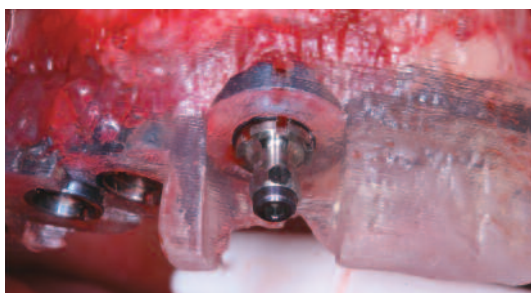
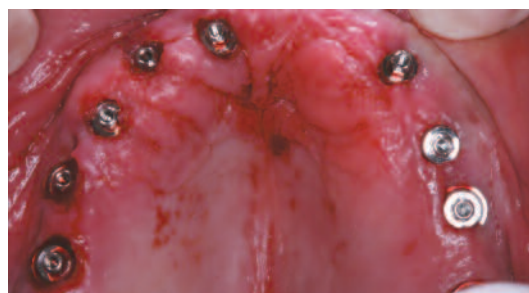

Fig. 24



amount of soft tissue. In order to optimize the aesthetic results, the soft tissues were replaced with gingival colored acrylic resin. This decreased the size of the artificial teeth and resulted in a much more natural appearing restoration.

The wax patterns and framework were invested conventionally, in a denture-processing flask. The wax was boiled out, and tooth-colored acrylic resin was packed into the tooth positions in the mold. Gingival colored acrylic resin was packed into the mold to replicate the gingival tissues being replaced with the provisional prosthesis. The resin was processed, the restoration was remounted on the articulator, and the occlusal error associated with processing was corrected (Fig. 18). The restoration was finished and polished (Fig. 19).

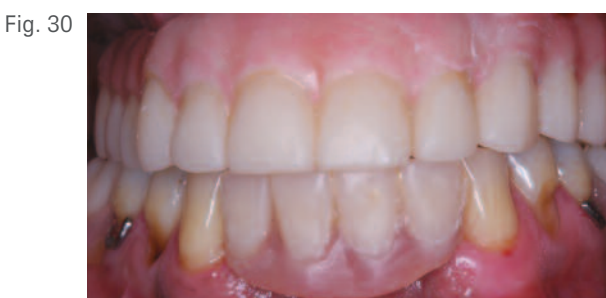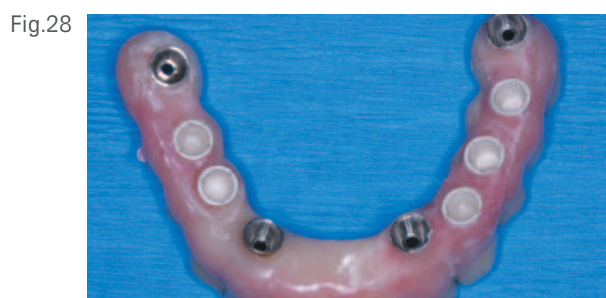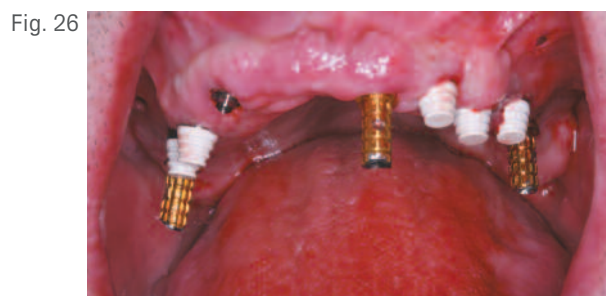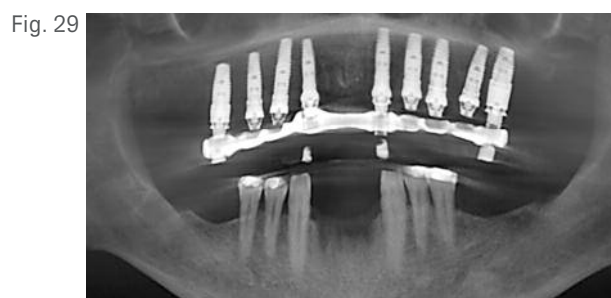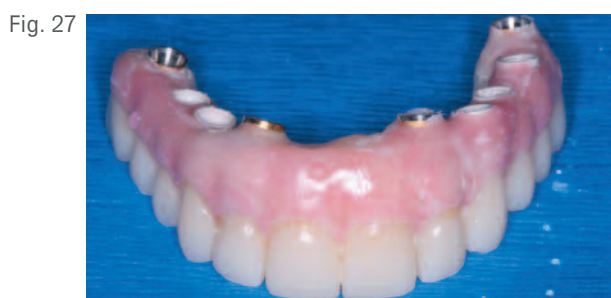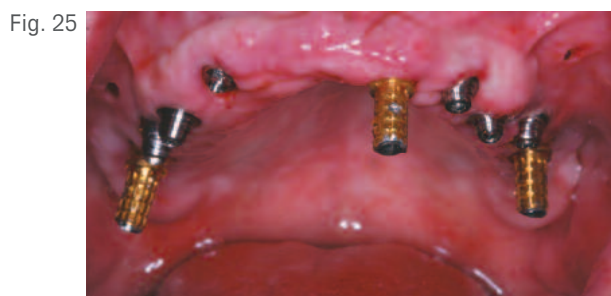
Figure 20 shows the intaglio surface of the provisional restoration. Note that only one temporary cylinder (in tooth site 7 [12]) was processed into the restoration. This facilitated the pickup of the temporary cylinders intraorally. If the provisional restoration is processed with all of the restorative

components, the restoration will be unlikely to align properly with the implants and abutments, due to the volumetric shrinkage associated with polymerization of acrylic resin.

Surgical Treatment

On the day of surgery, the patient received local anesthesia. The Surgical Guide was positioned intraorally and secured with one fixation screw (Fig. 21). The Tissue Punch was selected from the Tapered Navigator® Surgical Kit and passed through the Surgical Guide's Master Tubes at 300rpm to mark the implant locations. The palatal fixation screw and Surgical Guide were removed, and the soft-tissue plugs were removed with a tissue forceps, completely exposing the alveolar bone of the planned implant sites (Fig. 22).

The Surgical Guide was replaced intraorally and secured with three fixation screws. The Cortical Perforator was used until the predefined manufactured stop on the drill made contact with the Surgical Guide. This depth-specific feature on all drills allows for precise depth control. Appropriate length twist drills dictated



by the Surgical Plan were advanced into the osteotomies at 1200rpm. Then appropriate Countersink and Shaping Drills were used at 800rpm. Bone Taps were used as needed, based on the bone quality at each osteotomy site. Per the plan, Navigator® Implant Mounts were selected from the kit and mounted to the appropriate-sized Full OSSEOTITE® Certain® Tapered Implants (FOSS). Nine implants were placed into the prepared osteotomies at 20rpm (Fig. 23). The implants ranged in diameter from 3.25mm to 5mm and in length from 10mm to 15mm. The Implant Mounts and the Surgical Guide were removed.

Provisional Prosthesis Fabrication

The Low Profile Abutments used in the laboratory for fabrication of the provisional restoration were placed into their respective implants and torqued to 20Ncm (Fig. 24). A combination of non-hexed Low Profile Abutment Temporary Cylinders and QuickBridge® Titanium Temporary Cylinders were placed onto the abutments (Fig. 25). The QuickBridge Titanium Temporary Cylinders received QuickBridge Caps

(Fig. 26). This portion of the provisional restoration was to be cement-retained, with the remaining portion screw-retained. The provisional restoration was secured to the implant in tooth site 7 [12] with a try-in abutment screw. Note that the implant temporary cylinder processed into the provisional restoration was non-hexed. The provisional restoration was therefore free to rotate on the implant. A Low Profile Abutment Temporary Cylinder was placed on the contralateral abutment (tooth site 10 [22]). The restoration was centered, and clearance between the restoration and the temporary cylinder was noted.

Autopolymerizing acrylic resin was flowed around the temporary cylinder and into the intaglio surface of the restoration. The restoration was screwed into the implant in the maxillary right lateral incisor site, and the patient was guided into centric occlusion. This material was allowed to set, then the provisional restoration was removed, along with excess acrylic resin on the intaglio surface of the restoration. Autopolymerizing acrylic resin was then flowed around the

remaining abutment temporary cylinders and also placed into the intaglio surfaces of the provisional restoration in the remaining seven implant positions. The restoration was repositioned intraorally in the maxillary lateral incisor sites and attached to the abutments with retaining screws. The acrylic resin was allowed to set, then the screws were loosened and the restoration was removed. The appropriate abutment analogs were placed into the temporary cylinders with laboratory waxing screws. This maintained the integrity of the machined interfaces of the implant-restorative platforms of the restorative components within the provisional restoration. Acrylic resin was used to fill the voids, and the provisional restoration was finished, polished (Figs. 27 and 28), and then resealed.

The screws on the four implants were tightened to 10Ncm of torque with a Low Torque Indicating Ratchet Wrench (BIOMET 3i). The screw-access openings were restored with cotton pellets and composite resin. A periapical radiograph was taken (Fig. 29). The patient was given post-operative instructions and medications. He was discharged in excellent condition with the maxillary fixed provisional restoration in place (Fig. 30).

A CBCT post-operative scan was taken to evaluate the fit of the prosthesis. The patient was seen five days post-operatively, given oral hygiene instructions, and appointed to return in three months for commencement of the definitive restorative phase.

Clinical Relevance

This clinical presentation demonstrates the treatment of a patient with advanced periodontitis, using a combination of conventional removable prosthodontic techniques and implant therapy. Treatment planning was accomplished using state-of-the-art CBCT scanning. Precise implant placement was identified pre-operatively, along with the patient's anatomical conditions and the number and positions of the implants required. Accurate abutment selection was accomplished pre-operatively. The provisional restoration was fabricated predictably in the laboratory without salivary or hemorrhagic contamination and was reinforced with a cast-metal framework that insured its longevity. Finally, the patient received a state-of-the-art prosthesis that completely satisfied his desire to live without a removable maxillary denture. All this was accomplished in one surgical visit.

Robert A. del Castillo, DMD



Dr. del Castillo received his dental degree and his Certificate in Periodontics from Tufts University, School of Dental Medicine. He is a member of the American Academy of Periodontology, the Florida Society of Periodontists and the Academy of Osseointegration. He is an Adjunct Clinical Professor in the Department of Periodontics at Tufts University School of Dental Medicine and a Clinical Assistant Professor in the Department of Periodontics at Maryland University Dental School. He lectures both nationally and internationally. He has published on regenerative and implant therapy and is on the editorial review board of The Journal of Prosthodontics. Dr. del Castillo maintains a private practice, limited to periodontics with a strong emphasis on implant and regenerative therapies in Miami Lakes, Florida.

Thomas Peterson, CDT, MDT



Mr. Peterson became a Certified Dental Technician in 1986 and a Master of Dental Technology in 1995. He graduated from the Harvard Seminars in Implant Dentistry program in 1988 and received the John Griffin Technician of the Year award in 2007. He has lectured extensively on dental implant technology and is an active member of the Academy of Osseointegration. Currently he is president of NORTSHORE Dental Laboratories, Inc. in Lynn, MA.

[†]The contributing clinician has a financial relationship with BIOMET 3i LLC resulting from speaking engagements, consulting engagements, and other retained services.

WORLD-CLASS IS IN SESSION.
YOUR SEAT IS WAITING.



REV A 11/11